



# Complete Atrioventricular Block as a First Presentation of Arrhythmogenic Right Ventricular Cardiomyopathy in a Middle-Aged Male: A Nouvel Clinical Entity

H. Bendahou<sup>a</sup>, M. Njie<sup>a\*</sup>, Y. Ettagmouti<sup>a</sup>, M. Haboub<sup>a,b++</sup>,  
S. Arous<sup>a,b++</sup>, G. Bennouna<sup>a,b++</sup>, A. Drighil<sup>a,b++</sup>,  
L. Azzouzi<sup>a,b++</sup> and R. Habbal<sup>a,b++</sup>

<sup>a</sup> Department of Cardiology P37, Ibn Rochd University Hospital, Casablanca, Morocco.

<sup>b</sup> Faculty of Medicine and Pharmacy, Hassan II University of Casablanca, Casablanca, Morocco.

## **Authors' contributions**

*This work was carried out in collaboration among all authors. All authors read and approved the final manuscript.*

## **Article Information**

### **Open Peer Review History:**

This journal follows the Advanced Open Peer Review policy. Identity of the Reviewers, Editor(s) and additional Reviewers, peer review comments, different versions of the manuscript, comments of the editors, etc are available here: <https://www.sdiarticle5.com/review-history/100427>

**Case Study**

**Received: 22/03/2023**

**Accepted: 26/05/2023**

**Published: 03/06/2023**

## **ABSTRACT**

Arrhythmogenic right ventricular cardiomyopathy/dysplasia (ARVC/D) is a rare inherited cardiac disease that presents with progressive right ventricular (RV) dysfunction due to fibro-fatty replacement of the myocardium and associated with an elevated risk of ventricular arrhythmias and sudden cardiac death. ARVC/D has a predominantly autosomal dominant inheritance, although recessive forms associated with a cutaneous phenotype, such as Naxos disease and Carvajal

<sup>++</sup> Professor;

\*Corresponding author: Email: malick1njie@hotmail.com;

syndrome, are also observed. The golden standard for diagnosing ARVC/D is an endomyocardial biopsy demonstrating fibro-fatty replacement. Our case concerns a middle-aged male patient with rare bradyarrhythmia (complete atrioventricular block) associated with signs and symptoms of right heart failure who was diagnosed with arrhythmogenic right ventricular cardiomyopathy ARVC died shortly upon admission at the emergency department.

**Keywords:** Complete atrioventricular block; arrhythmogenic right ventricular cardiomyopathy / dysplasia; task force criteria.

## 1. INTRODUCTION

“Arrhythmogenic right ventricular cardiomyopathy/ dysplasia (ARVC/D) is characterized by progressive replacement of myocardial cells by fibro-fatty tissue, initially only in the right ventricle, but it can extent to the left ventricle as well” [1]. “The diagnosis is made with the Task Force Criteria” [1]. “The estimated prevalence is 1:5,000 individuals” [2]. “Genetic alterations underlying ARVC are often mutations in one of the cardiac desmosome genes” [3]. “These mutations are known for their phenotype diversity within families” [4]. “The golden standard for diagnosing ARVC/D is an endomyocardial biopsy demonstrating fibro-fatty replacement” [5]. ARVC is associated with ventricular tachyarrhythmias giving rise to syncope or sudden cardiac death. However, we present a middle-aged male patient with bradyarrhythmia (3<sup>rd</sup> degree atrioventricular block) who was diagnosed with arrhythmogenic right ventricular cardiomyopathy (ARVC) died shortly upon admission at the emergency department.

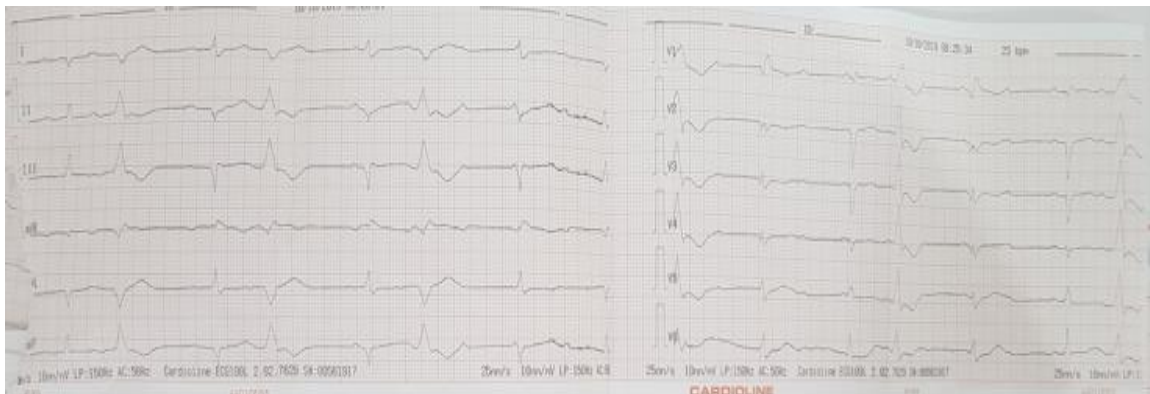
## 2. CLINICAL PRESENTATION

51-year-old patient who was apparently asymptomatic till 2 months back presented to the

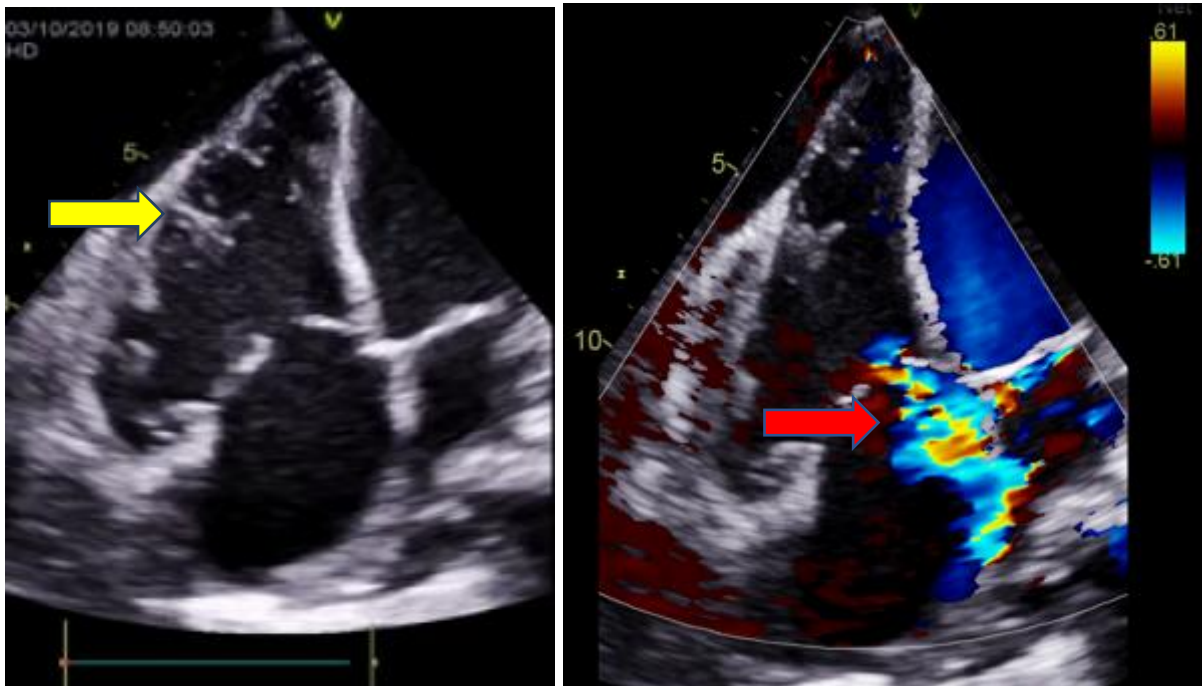
cardiology emergency department for progressive dyspnea on exertion stage III NYHA and repetitive post exertional syncope. On examination, patient was dyspneic stage III NYHA, with no chest pain or palpitation, associated with three repetitive post exertional of syncope. Blood pressure was (BP) at 110/60 mmHg, and heart rate (HR) at 40 beats per minute (bpm) associated with signs of right heart failure (oedema of the lower limbs, Turgor of the jugular veins).

The electrocardiogram (ECG) findings showed a complete atrioventricular block with an escape rhythm of 40 bpm (Fig. 1) associated with a completely right bundle block (RBB) and premature ventricular excitation.

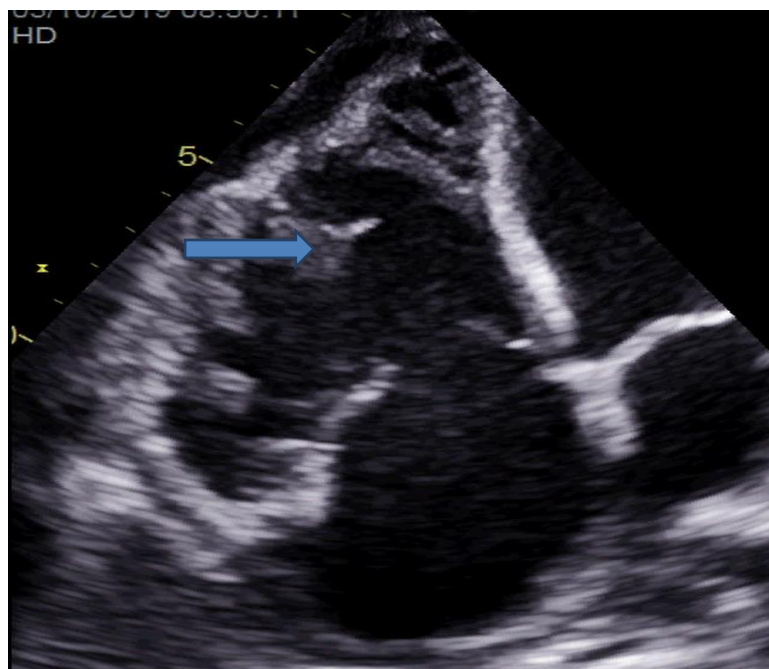
Transthoracic echocardiography (TTE) performed on the patient showed a non-dilated left ventricle (LV) with a LVEF of 30% measured by bipolar Simpson method, and a very dilated right ventricle (Basal diameter of the right ventricle = 51mm). A dyskinetic free wall of the right ventricle was observed associated with an aneurysm, and multiple trabeculations, in severe systolic dysfunction. We also noted a functional laminar tricuspid regurgitation (TR) due to dilation of the tricuspid ring and coaptation defect (Fig. 2).



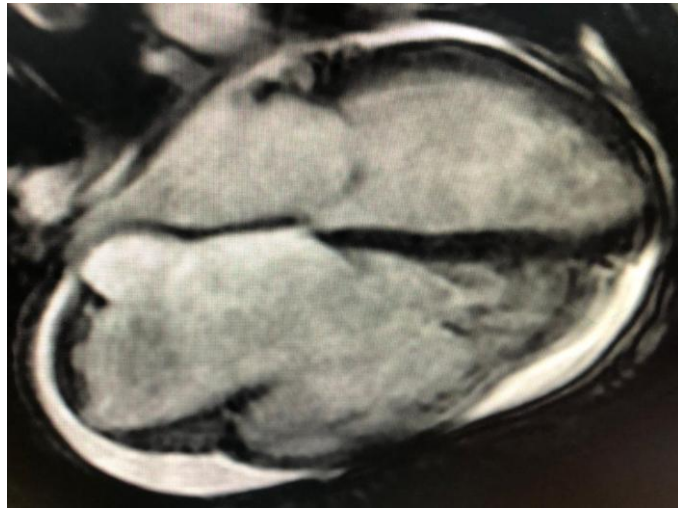
**Fig. 1. Electrocardiogram (ECG): Complete atrioventricular block, associated with RBB and premature ventricular excitation**



**Fig. 2a.** Transthoracic echocardiography (TTE): 4 chambers apical view: showing a very dilated right ventricle with aneurysms, and multiple trabeculations (yellow arrow)  
**Fig. 2b.** Doppler TTE: 4 chambers apical view: functional laminar tricuspid regurgitation (TR) [red arrow] and a mild pericardial effusion on the surrounding walls of the heart cavities



**Fig. 2c.** TTE: 4 chambers apical view: presence of spontaneous contrast and thrombus trabeculae (blue arrow) in highly dilated left ventricle



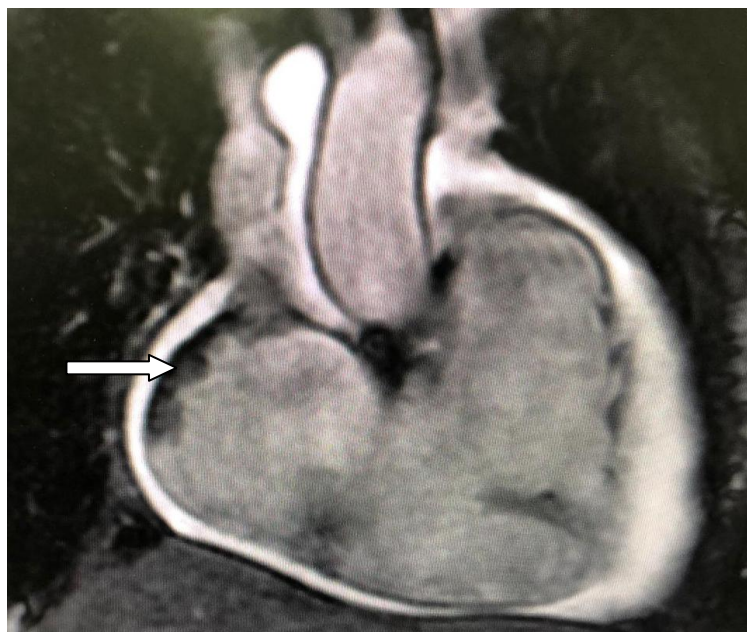**Fig. 3. Cardiac MRI: cross section view: showing a dilated right ventricle with an altered systolic function (ejection fraction of 21%) without late enhancement signal to witness fibrose depot**

The blood assessment showed an increased level of NT Pro BNP (NT Pro BNP:10000ng/l) and that of the heart enzyme troponin (Highly sensitive troponin=70ng/l).

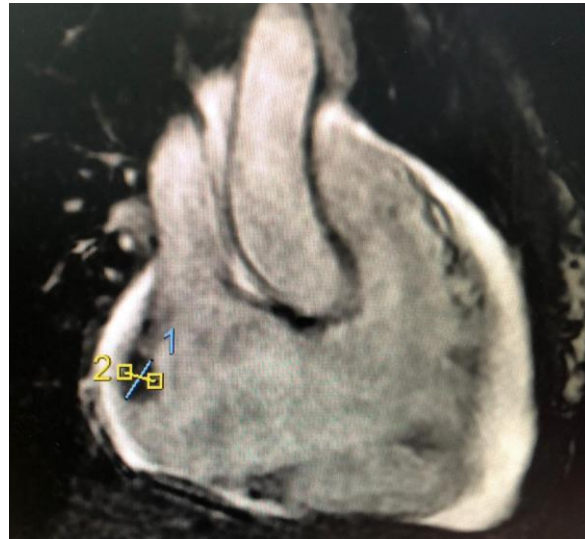Faced with this clinical outcome, a cardiac magnetic resonance imaging (cMRI) was performed urgently, objectifying a dilated and severe right ventricle (RV) dysfunction. A global RV hypokinesia with an indexed right ventricle tele diastolic volume (RV DTV) of 192ml/m<sup>2</sup> and

a 21% ejection fraction of the right ventricle (EFRV) Fig. 3.

cMRI also identified multiple aneurysms and trabeculations located at the level of the RV which interest its free wall (Fig. 4) and the infundibulum region. The right atrium (RA) was also dilated (Index volume of the right atrium= 90ml/m<sup>2</sup>), presences of a thrombus at the base of the RA measuring 14mm x 10mm in diameter. Hypertrophy of the RV wall (Fig. 5).



**Fig. 4. Cardiac MRI: Hypersignal T2: Hypertrophy of the right ventricle with multiple aneurysms of its free wall, presence of mild pericardial effusion**



**Fig. 5. Cardiac MRI: Thrombus at the base of the right atrium associated with a dilated right ventricle without late enhancement to witness fibrose tissue depot**

The LV was non-dilated, non-hypertrophied (indexed LV tele diastolic volume=62ml/m<sup>2</sup> and tele systolic volume=45.3ml/m<sup>2</sup>) with an altered systolic function. Diffuse mild pericardial effusion associated mild bilateral pleural effusion with no remarkable fibrose tissues. This cardiac finding affirmed the diagnosis of arrhythmogenic right ventricular cardiomyopathy with 2 major criterions (Important dilatation of the RV, RV wall motion abnormalities with multiple aneurysms), and 2 minor criterions (LBB and frequent premature ventricular excitation).

The patient was immediately rushed to catheterization room for coronary artery angiography and pacemaker, but the evolution was rapidly fatal, progressing to death after an extreme bradyarrhythmia and asystole. Autopsy was not authorized by family thus difficult to exclude another possible differential diagnosis like cardiac sarcoidosis.

### 3. DISCUSSION

In this case report, we describe an adult patient with a symptomatic high degree atrioventricular conduction block before ARVC became overt. He presented with a coincidentally found third degree atrioventricular block type after repetitive post exertional syncope, and the transthoracic echocardiography (TTE) findings suspected an ARVC/D affirmed by cardiac MRI.

“Arrhythmogenic right ventricular cardiomyopathy/ dysplasia (ARVC/D) is an

uncommon inherited cardiac disease characterized by progressive right ventricular (RV) dysfunction due to fibro-fatty replacement of the myocardium and associated with high risk of ventricular arrhythmias and sudden cardiac death” [6]. “ARVC/D has a predominantly autosomal dominant inheritance, although recessive forms associated with a cutaneous phenotype, such as Naxos disease and Carvajal syndrome, are also observed” [7]. A cross-sectional study aimed to assess the prevalence and clinical significance of bradyarrhythmias in ARVC was carried out by Erpang Liang et al. from May 1995 to December 2017 [8] showed that “bradyarrhythmias were commonly seen in ARVC, and intraventricular conduction block (ICB) was the most common type”. In our case AV block was the first clinical presentation.

“Classically, ARVC/D usually presents between the second and fourth decades of life with syncope, symptomatic arrhythmias, or sudden cardiac death (SCD)” [9]. In our case, patient was admitted for repetitive post exertional syncope and heart failure (HF) symptoms who died later before heart intervention. These symptoms were all combined in our patients who had a pejorative prognosis. A study reports that “HF hospitalization has a significant relation with malignant clinical course in ARVC patients, and first-degree AVB at baseline is strongly associated with HF hospitalization” [10].

“There is no single diagnostic test for ARVC/D. The diagnosis is made based on major and minor clinical, electrical, and imaging criterions

that have been devised by expert consensus of the Task Force Criteria (TFC) originally proposed in 1994 and further revised in 2010" [1,6]. The diagnosis was certain with major and minor criteria confirming the diagnosis. TTE and cardiac MRI play an important role in diagnosis confirmation as well as deferential diagnosis of ARVC/D [10].

"The American College of Cardiology, the American Heart Association and the European Society and Cardiology recommended ICD implantation for the prevention of SCD events" [11]. "Risk stratification and indication to ICD implantation in ARVC/D has been proposed by an international task force consensus statement" [12]. "Patients who present congestive heart failure signs and symptoms are managed with diuretics, angiotensin-converting enzyme (ACE) inhibitors or aldosterone inhibitors, and in some cases heart transplantation is considered in terminal stages of the disease. Anticoagulation may be used in ARVC/D patients with large, hypokinetic RV and slow blood flow because of the risk of thrombosis" [13]. "Therapy with beta blockers, sotalol or amiodarone may be effective in suppressing ventricular arrhythmias and possibly in preventing sudden cardiac death" [14]. "Management of family members of patients with ARVC/D is complex due to the incomplete penetrance and variable expressivity nature of the disease" [15]. In our case, access to screen family members for genetic disorder was difficult.

Atrioventricular conduction abnormalities have only rarely been described in patients already diagnosed with ARVC [16]. Our patient presented both symptoms of bradyarrhythmia and heart failure which are rare entities as heart failure signs a rarely neglected by patients.

#### 4. CONCLUSION

The case report is a rare presentation of a rare cardiomyopathy. ARVC/D is an inherited disease characterized by fibro-fatty replacement of the right ventricular myocardium, which significantly increases the risk of paroxysmal ventricular arrhythmias and SCD. It is relevant for concerned physicians (cardiologist) and also for the emergency carers to be aware of this pathology.

Diagnosis is based on the 2010 modified Task Force criteria, requiring clinical, family history, electrocardiography, and imaging. Diagnosis may be confirmed by endomyocardial biopsy.

Screening of this pathology should be encouraged to identify individuals with a family history of AVRC/D or identified genes for better management.

#### CONSENT

As per international standard or university standard, patient(s) written consent has been collected and preserved by the author(s).

#### ETHICAL APPROVAL

As per international standard or university standard written ethical approval has been collected and preserved by the author(s).

#### ACKNOWLEDGEMENT

I thank the whole Department of Cardiology P37 and the Department of emergency radiology, university teaching hospital Ibn Rochd Casablanca for their outstanding collaboration in the support of this work.

#### COMPETING INTERESTS

Authors have declared that no competing interests exist.

#### REFERENCES

1. Danielle E Burghouwt, Janneke AE Kammeraad, Paul Knops, Frederik A du Plessis, Natasja MS de Groot. Bradyarrhythmias: First presentation of arrhythmogenic right ventricular cardiomyopathy? J Clin Med Res. 2015; 7:278-281.
2. Hamilton RM, Fidler L. Right ventricular cardiomyopathy in the young: An emerging challenge. Heart Rhythm. 2009;6:571-575.
3. Den Haan AD, Tan BY, Zikusoka MN, Llado LI, Jain R, Daly A, Tichnell C, et al. Comprehensive desmosome mutation analysis in north americans with arrhythmogenic right ventricular dysplasia/cardiomyopathy. Circ Cardiovasc Genet. 2009;2:428-435.
4. Quarta G, Muir A, Pantazis A, Syrris P, Gehmlich K, Garcia-Pavia P, Ward D, et al. Familial evaluation in arrhythmogenic right ventricular cardiomyopathy: impact of genetics and revised task force criteria. Circulation. 2011;123 n:2701-2709.
5. Peters S, Trummel M, Koehler B, Westermann KU. Mechanisms of syncope

- in arrhythmogenic right ventricular dysplasia-cardiomyopathy beyond monomorphic ventricular tachycardia. *Int J Cardiol.* 2006;106 :52-54.
6. Ka Hou Christien Li, George Bazoukis, Tong Liu, Guangping Li, William K K Wu, Sunny Hei Wong, Wing Tak Wong, Yat Sun Chan, Martin C S Wong, Katharina Wassilew, Vassilios S Vassiliou, Gary Tse. Arrhythmogenic right ventricular cardiomyopathy/ dysplasia (ARVC/D) in clinical practice. *J Arrhythm* 2017; 21(34):11-22.
  7. Sultan FA, Ahmed MA, Miller J, Selvanayagam JB. Arrhythmogenic right ventricular cardiomyopathy with biventricular involvement and heart failure in a 9-year old girl. *J Saudi Heart Assoc.* 2017;29:139–42.
  8. Erpeng Liang, Lingmin Wu, Siyang Fan, Xiaofei Li, Feng Hu, Lihui Zheng, Xiaohan Fan, Gang Chen, Ligang Ding, Yan Yao. Bradyarrhythmias in Arrhythmogenic Right Ventricular Cardiomyopathy *Am J Cardiol.* 2019;123:1690-1695.
  9. Julia H. Indik and Frank I. Marcus. Arrhythmogenic Right Ventricular Cardiomyopathy / Dysplasia. *Indian Pacing and Electrophysiology Journal.* Available: [www.ipej.org](http://www.ipej.org)
  10. Kimura Y, Noda T, Matsuyama TA, Otsuka Y, Kamakura T, Wada M, et al. Heart failure in patients with arrhythmogenic right ventricular cardiomyopathy: What are the risk factors? *Int J Cardiol.* 2017;241:288-294.
  11. Schinkel AF. Implantable cardioverter defibrillators in arrhythmogenic right ventricular dysplasia/ cardiomyopathy: Patient outcomes, incidence of appropriate and inappropriate interventions, and complications. *Circ Arrhythm Electrophysiol.* 2013;6:562–8.
  12. Corrado D, Wichter T, Link MS, et al. Treatment of arrhythmogenic right ventricular cardiomyopathy/ dysplasia: An international task force consensus statement. *Eur Heart J.* 2015;36: 3227–37.
  13. Wlodarska EK, Wozniak O, Konka M, Rydlewska-Sadowska W, Biederman A, Hoffman P. Thromboembolic complications in patients with arrhythmogenic right ventricular dysplasia/cardiomyopathy. *Europace.* 2006;8:596–600.
  14. Danielle E Burghouwt, Janneke AE Kammeraad, Paul Knops, Frederik A du Plessis, Natasja MS de Groot, Bradyarrhythmias: First Presentation of Arrhythmogenic Right Ventricular Cardiomyopathy? *J Clin Med Res.* 2015;7:278-281.
  15. Kirubakaran S, Bisceglia C, Silberbauer J, et al. Characterization of the arrhythmogenic substrate in patients with arrhythmogenic right ventricular cardiomyopathy undergoing ventricular tachycardia ablation. *Europace.* 2017;19: 1049–62.
  16. Pu JL, Wang HT, Liu TK, Ma KJ, Li N, Yao Y, Chu JM, et al. [Clinical and ECG features of arrhythmogenic right ventricular cardiomyopathy: a retrospective analysis of 31 cases]. *Zhonghua Xin Xue Guan Bing Za Zhi.* 2007;35:24-27.

© 2023 Bendahou et al.; This is an Open Access article distributed under the terms of the Creative Commons Attribution License (<http://creativecommons.org/licenses/by/4.0>), which permits unrestricted use, distribution, and reproduction in any medium, provided the original work is properly cited.

Peer-review history:

The peer review history for this paper can be accessed here:  
<https://www.sdiarticle5.com/review-history/100427>