



# Upper Gastrointestinal Endoscopy in a Sub-Urban Population of South-East Nigeria: A 2.5 Year Analysis

Christopher Nonso Ekwunife <sup>a\*</sup>,  
Uchechi Chukwudike Ekpemiro <sup>a</sup>,  
Ifeanyichukwu Emmanuel Ihedoro <sup>a</sup>  
and Cornelius C. Chukwuegbo <sup>b</sup>

<sup>a</sup> Department of Surgery, Federal Medical Centre, Umuahia, Nigeria.

<sup>b</sup> Department of Anatomical Pathology, Federal Medical Centre, Umuahia, Nigeria.

## **Authors' contributions**

*This work was carried out in collaboration among all authors. All authors read and approved the final manuscript.*

## **Article Information**

### **Open Peer Review History:**

This journal follows the Advanced Open Peer Review policy. Identity of the Reviewers, Editor(s) and additional Reviewers, peer review comments, different versions of the manuscript, comments of the editors, etc are available here: <https://www.sdiarticle5.com/review-history/99354>

**Original Research Article**

**Received: 17/08/2023**  
**Accepted: 25/10/2023**  
**Published: 14/11/2023**

## **ABSTRACT**

**Background:** Gastrointestinal endoscopy is a diagnostic and therapeutic procedure vital for the management of gastrointestinal pathologies. This is indispensable in modern medicine. We report our early experience with video gastrointestinal endoscopy at the Federal Medical Centre Umuahia, a tertiary hospital in southeast Nigeria.

**Methods:** A cross-sectional observational study of all patients who underwent esophagogastroduodenoscopy(OGD) at the Federal Medical Centre Umuahia in the two and half year period between July 2020 and December 2022 was done.

**Results:** The patients comprised 60 females (51.7%) and 56 males(48.3%). The mean age of the patients was  $55.3 \pm 17.0$  with a range of 14-90 years. Dyspepsia and gastrointestinal haemorrhage accounted for over three-quarters of the indication for endoscopy. The most frequent findings at

\*Corresponding author: Email: [chrisekwunife@yahoo.co.uk](mailto:chrisekwunife@yahoo.co.uk);

endoscopy were features of gastritis, followed by gastroduodenal erosions. Twenty-three (19.8%) of the patients had normal findings at endoscopy. Mass lesions were seen in 9.5% of the cases.

**Conclusion:** The diagnostic yield of endoscopy is high in appropriate indications. The appreciable proportion of oesophago-gastric tumours seen should stimulate further research. Despite the infancy of our practice, our outcomes were similar to other established centres in our nation.

**Keywords:** *Gastrointestinal endoscopy; oesophago-gastric tumours; therapeutic procedure; endoscopy.*

## 1. INTRODUCTION

Gastrointestinal endoscopy is a diagnostic and therapeutic procedure vital for the management of gastrointestinal pathologies. This is indispensable in modern medicine. In the developing world, significant challenges remain regarding the optimal utilization of this technology. This is particularly acute in sub-Saharan Africa where there are challenges of dearth of endoscopists, lack of adequate investment in endoscopic equipment, epileptic electric power supply and patients paying out of pocket for medical expenses. [1, 2]. The heightened awareness of the benefits of endoscopy services has led to increased waiting lists in Western countries. This has led to concerns about the appropriateness of endoscopy referrals in open-access settings [3]. Even in an African setting, open-access endoscopy yields an enormous throughput of patients signifying the pent-up demand for these services.[4] Gastrointestinal endoscopy in sub-Saharan Africa is commonly performed by surgeons and gastroenterologists. Physicians in the region have reported a wide variety of gastrointestinal diseases for which they do not have easy access to basic diagnostic gastrointestinal endoscopic service [5]. Therapeutic endoscopy is even more limited in scope. Barriers that perpetuate these problems include lack of endoscopic equipment, dearth of endoscopists, cost related to equipment maintenance, and patient affordability of the procedures [6]. However, despite earlier setbacks, endoscopy practice has become increasingly entrenched in the growing number of public and private health institutions in Nigeria[7]. Here, we report our early experience with video gastrointestinal endoscopy at the Federal Medical Centre Umuahia, a tertiary hospital in southeast Nigeria.

## 2. METHODS

### 2.1 Study Setting

The study was conducted at the Federal Medical Centre, Umuahia, Nigeria. The hospital is a

referral centre that caters to close to 5 million people in the southeastern part of the country. Gastrointestinal endoscopy was initiated in July 2020 at our institution. Patients were booked for procedures from the Accident & Emergency unit, Surgery and Gastroenterology clinics, and hospital wards. The endoscopists were both surgeons and gastroenterologists.

### 2.2 Study Population

A cross-sectional observational study of all patients who underwent oesophago-gastroduodenoscopy(OGD) at the Federal Medical Centre Umuahia in the two and half year period between July 2020 and December 2022 was done. The endoscopy suite record database was reviewed to extract the following data points: patient demographics, indications for the procedures, and findings. There was no abnormality discovered in 23(19.8%) patients

### 2.3 Endoscopy Procedure

A pre-endoscopy assessment, including viral hepatitis screening, was performed for all patients. Informed consent was obtained from all participants. The endoscopy suite is located within the theatre complex and is equipped with a single Olympus Evis-Exera CLE-145 gastroscope. The patients were premedicated with a 10% lignocaine pharyngeal spray. Occasionally, intravenous hyoscine and/or midazolam were added depending on the endoscopist's preference. Paediatric patients were routinely administered propofol anaesthesia.

### 2.4 Data Analysis

Data entry and analysis were performed using IBM SPSS Statistics version 28.0.1 (SPSS, Chicago, IL, USA). Categorical data are reported as proportions, whereas continuous variables were described by the use of mean/median.

### 3. RESULTS

Between July 2020 and December 2022, a total of 186 gastrointestinal endoscopies were performed, 116 of which were OGDs. The patients' ages ranged from 14 to 90 years, with a mean of 55.3(±17.00). Sixty females and 56 males were included in this study. The most common indication for upper gastrointestinal endoscopy was dyspepsia, closely followed by gastrointestinal haemorrhage (Table 1). Both accounted for three-quarters of all OGD indications. Features of gastritis and gastroduodenal erosions were the top two abnormalities seen at OGD and comprised 42.2% (n=59) of the findings (Table 2). Among the cases who have gastrointestinal haemorrhage the commonest finding was gastric/duodenal erosions followed by gastric ulcer and duodenal ulcer (Fig 1). Variceal haemorrhage was the finding in only two (5%) cases.

### 4. DISCUSSION

Dyspepsia was the commonest indication for OGD in our series, and is consistent with various recent reports across Nigeria [8-10]. In fact a report from Ghana [11] showed dyspepsia to account for 80% of indications for OGD, which was similar to findings from Benin [12]. There is a perception among the population that upper abdominal pain is almost synonymous with peptic ulcer disease. The medical practitioners in the sub-region were not immune to this influence,

as shown in an earlier publication from Ile-Ife, where the pre-referral diagnosis of peptic ulcer disease was made in 67.6% of patients sent for OGD [13]. This reinforces the need for pre-endoscopy assessment for the proper classification of the indication and determination of the appropriateness of a specific OGD request.

Gastrointestinal bleeding ranked second in our indications list, as was also seen in Ido-Ekiti [14] and a district hospital in Ghana [15], although it accounted for a much lower value of 2.2% in a larger volume study in Kumasi [11]. In our population, there are concerns regarding the abuse of non-steroidal anti-inflammatory drugs [12]. The higher component of gastrointestinal haemorrhage in our study could be due to the fact that we did not perform open-access endoscopies.

The most common finding of gastritis follows similar trend across studies [9, 13-15]. In contrast a normal finding was seen in half of the patients scoped in Kumasi.[11] Furthermore, lesions suspicious for esophageal carcinoma are the most commonest finding (34%) in Mbale, Uganda [16]. This could be attributed to the referral pattern in hospitals located in a population with a high incidence of esophageal malignancies. In our study, findings suggestive of esophageal malignancies(tumours and strictures) occurred in only 4.3% of the examined patients.

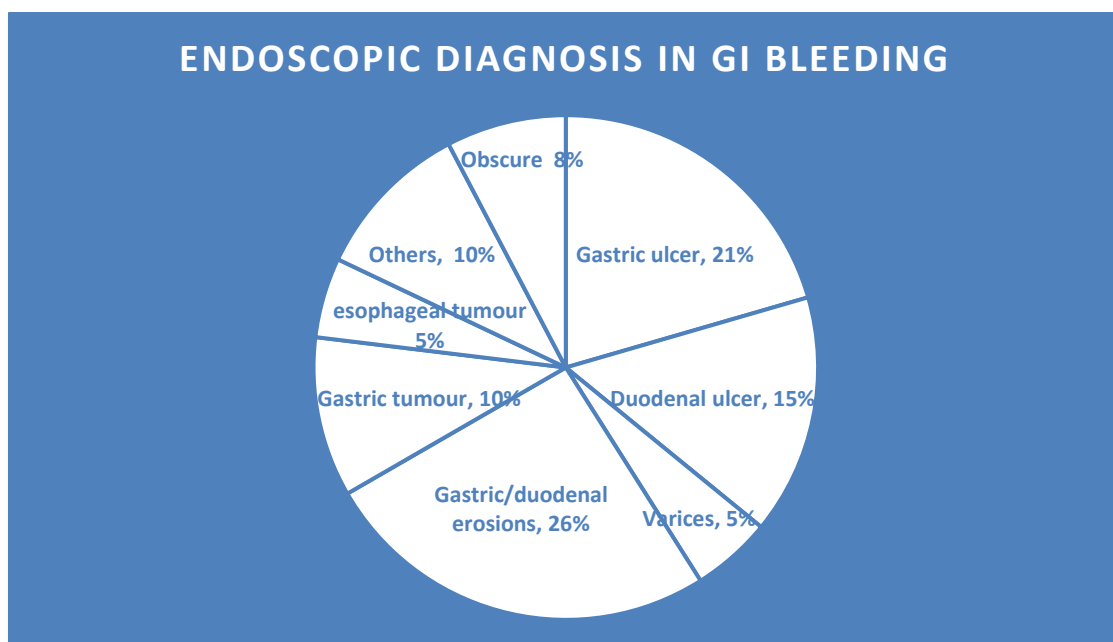


Fig. 1. Endoscopic diagnoses in cases with GI bleeding

**Table 1. Indications for endoscopy**

Indication	Frequency	Percent	Valid Percent	Cumulative Percent
Anaemia	1	.9	.9	.9
Dyspepsia	47	40.5	40.5	41.4
Dysphagia	5	4.3	4.3	45.7
Follow up	3	2.6	2.6	48.3
Gastric outlet obstruction	6	5.2	5.2	53.4
GERD	6	5.2	5.2	58.6
GI Bleeding	42	36.2	36.2	94.8
Persistent vomiting	2	1.7	1.7	96.6
Suspected colon cancer	1	.9	.9	97.4
Suspected gastric cancer	3	2.6	2.6	100.0
<b>Total</b>	<b>116</b>	<b>100.0</b>	<b>100.0</b>	

**Table 2. Findings at endoscopy**

Findings	Frequency	Percent	Valid Percent	Cumulative Percent
Valid Gastritis	28	24.1	24.1	24.1
Gastroduodenal erosions	21	18.1	18.1	42.2
Oesophagitis	3	2.6	2.6	44.8
Oesophageal tumour	3	2.6	2.6	47.4
Oesophageal candidiasis	3	2.6	2.6	50.0
Oesophageal stricture	2	1.7	1.7	51.7
Duodenal ulcer	6	5.2	5.2	56.9
Gastric ulcer	8	6.9	6.9	63.8
Gastric tumour	9	7.8	7.8	71.6
Normal	23	19.8	19.8	91.4
Achalasia	2	1.7	1.7	93.1
Gastric diverticulum	1	.9	.9	94.0
Gastrointestinal stromal tumour	2	1.7	1.7	95.7
Oesophageal candidiasis, Duodenal erosion	1	.9	.9	96.6
Oesophageal varices	1	.9	.9	97.4
Oesophageal varices, GAVE, portal hypertensive gastropathy	1	.9	.9	98.3
Portal Hypertensive Gastropathy	1	.9	.9	99.1
Pyloric stenosis	1	.9	.9	100.0
<b>Total</b>	<b>116</b>	<b>100.0</b>	<b>100.0</b>	

There has been a decline in proportion of duodenal ulcer diagnosed at endoscopy in our environment, which may be attributable to widespread use/abuse of proton pump inhibitors [8,17]. The preponderance of gastric ulcers over duodenal ulcers was also noted in our study. The gastric ulcer to duodenal ulcer ratio (1.4: 1) shown in Port Harcourt [18] is similar to ours which was 1.3:1. Overall, peptic ulcer findings were seen in 12.1% of subjects, a figure almost

double that obtained in the aforementioned study.

The combination of mass lesions seen in the stomach (gastrointestinal tumour and gastric tumour) at 9.5%, where there was only a suspicion of gastric malignancy in 2.6% of endoscopy indications, points to the tendency to neglect alarm symptoms prevalent in our population.

In contrast to some reports from southern Africa the incidence of variceal haemorrhage is quite low in our environment. Variceal haemorrhage accounted for 24% of haematemesis in a report from Zambia [19] and 64% of cases of acute gastrointestinal bleeding presenting for endoscopy Malawi [6].

Limitations of our study include its retrospective nature and the small volume of the performed cases. It is hoped that as awareness of the benefits of endoscopy is created, a prospective study will be powered enough to provide further insights into gastrointestinal diseases in our part of the world.

## 5. CONCLUSION

Dyspepsia and gastrointestinal bleeding were the commonest reasons patients present for OGD in our setting. The most prominent abnormal findings were gastritis and gastroduodenal erosions. The appreciable proportion of oesophagogastric tumours seen should stimulate further research. Despite the infancy of our practice our outcomes were similar to other established centres in our nation.

## CONSENT

As per international standards or university standard, patients' written consent has been collected and preserved by the author(s).

## ETHICAL APPROVAL

As per international standards or university standard written ethical approval has been collected and preserved by the author(s).

## COMPETING INTERESTS

Authors have declared that no competing interests exist.

## REFERENCES

1. Hassan C, Aabakken L, Ebigbo A, Karstensen JG, Guy C, Dinis-Ribeiro M, Le Moine O, Vilmann P, Ponchon T. Partnership with African Countries: European Society of Gastrointestinal Endoscopy (ESGE) – Position Statement. *Endoscopy International Open*. 2018;6(10):E1247-E1255  
DOI: 10.1055/a-0677-2026
2. Chuks NS. Challenges of gastrointestinal endoscopy in resource-poor countries. *IntechOpen*; 2011.
3. Hassan CMD, Bersani GMD, Buri LMD, Zullo AMD, Anti MMD, Bianco MAMD, Di Giulio EMD, Ficano LMD, Morini SMD, Di Matteo GMD, Loriga PMD, Pietropaolo VMD, Cipolletta LMD, Costamagna GMD. Appropriateness of upper-GI endoscopy: An Italian survey on behalf of the Italian Society of Digestive Endoscopy. *Gastrointestinal Endoscopy*. 2007;65(6): 767-774  
DOI: 10.1016/j.gie.2006.12.058
4. Dakubo JC, Clegg-Lampsey JN, Sowah P. Appropriateness of referrals for upper gastrointestinal endoscopy. *West African Journal of Medicine*. 2011;30(5):342-347
5. Perl D, Leddin D, Bizos D, Veitch A, N'Dow J, Bush-Goddard S, Njie R, Lemoine M, Anderson ST, Igoe J, Anandasabapathy S, Shah B. Endoscopic capacity in West Africa. *African Health Sciences*. 2016;16(1):329-338  
DOI: 10.4314/ahs.v16i1.44
6. Mwachiro M, Topazian HM, Kayamba V, Mulima G, Ogutu E, Erkie M, Lenga G, Mutie T, Mukhwana E, Desalegn H, Berhe R, Meshesha BR, Kaimila B, Kelly P, Fleischer D, Dawsey SM, Topazian MD. Gastrointestinal endoscopy capacity in Eastern Africa. *Endoscopy International Open* 2021;9(11):E1827-E1836  
DOI: 10.1055/a-1551-3343
7. Malu AO. Gastrointestinal endoscopy in Nigeria. *Niger J Gastroenterol Hepatol*. 2020;12(2):33-39
8. Ijarotimi O, Soyoye DO, Adekanle O, Ndububa DA, Umoru BI, Alatise OI. Declining prevalence of duodenal ulcer at endoscopy in Ile-Ife, Nigeria. *South African Medical Journal*. 2017;107(9): 750  
DOI: 10.7196/SAMJ.2017.v10719.12342
9. Ismaila BO, Misauno MA. Gastrointestinal endoscopy in Nigeria--A prospective two year audit. *The Pan African Medical Journal*. 2013;14(22):22-22  
DOI:10.11604/pamj.2013.14.22.1865
10. Oluseyi Akande K, Oke To, Afuwape O, Adigun TA, Akere A, Aje A, Ola SO, Otegbayo JA. Spectrum and pattern of distribution of findings in patients with dyspepsia undergoing oesophago-gastro-duodenoscopy at a Tertiary Hospital in Ibadan, south west, Nigeria. *Alexandria Journal of Medicine* 2021; 57(1):151-156 .  
DOI: 10.1080/20905068.2021.1913890

11. Gyedu A, Yorke J. Upper gastrointestinal endoscopy in the patient population of Kumasi, Ghana: indications and findings. *The Pan African Medical Journal*. 2014;18(327):327-327. DOI: 10.11604/pamj.2014.18.327.4806
12. Odeghe EA, Adeniyi OF, Oyeleke GK, Keshinro SO. Use of alarm features in predicting significant endoscopic findings in Nigerian patients with dyspepsia. *The Pan African Medical Journal* 2019; 34(66): 66-66 DOI: 10.11604/pamj.2019.34.66.18848
13. Agbakwuru EA, Fatusi AO, Ndububa DA, Alatise OI, Arigbabu OA, Akinola DO. Pattern and Validity of Clinical Diagnosis of Upper Gastrointestinal Diseases in South-west Nigeria. *African Health Sciences*. 2006; 6(2):98-103
14. Oluwagbenga OO. Upper Gastrointestinal Endoscopy In Ido-Ekiti, Nigeria: A four-year review. *Open journal of Gastroenterology and Hepatology*. 2020:35. DOI: 10.28933/ojgh-2020-04-0905
15. Agyei-Nkansah A, Duah A, Alfonso M. Indications and findings of upper gastrointestinal endoscopy in patients presenting to a District Hospital, Ghana. *The Pan African Medical Journal* 2019; 34(82):82-82 DOI: 10.11604/pamj.2019.34.82.18002
16. Doe MJ, Bua E, Obbo JS, Bisso F, Olupot-Olupot P. Upper gastrointestinal endoscopy findings in Mbale Regional Referral Hospital, Eastern Uganda: A 10-year retrospective analysis. *African Health Sciences* 2021;21(2):919-926 . DOI: 10.4314/ahs.v21i2.54
17. Nwokediuko SC, Ijoma U, Obieniu O, Picardo N. Time trends of upper gastrointestinal diseases in Nigeria. *Annals of Gastroenterology*. 2012; 25(1):52-56.
18. Ray-Offor E, Opusunju KA. Current status of peptic ulcer disease in Port Harcourt metropolis, Nigeria. *African Health Sciences*. 2020;20(3):1446-1451. DOI: 10.4314/ahs.v20i3.50
19. Kayamba V, Sinkala E, Mwanamakondo S, Soko R, Kawimbe B, Amadi B, Zulu I, Nzaisenga J-B, Banda T, Mumbwe C, Phiri E, Munkonge P, Kelly P. Trends in upper gastrointestinal diagnosis over four decades in Lusaka, Zambia: A retrospective analysis of endoscopic findings. *BMC Gastroenterology* 2015;15(1):127-127 DOI: 10.1186/s12876-015-0353-8

© 2023 Ekwunife et al.; This is an Open Access article distributed under the terms of the Creative Commons Attribution License (<http://creativecommons.org/licenses/by/4.0>), which permits unrestricted use, distribution, and reproduction in any medium, provided the original work is properly cited.

*Peer-review history:*

*The peer review history for this paper can be accessed here:*  
<https://www.sdiarticle5.com/review-history/99354>