

Effects of Altitude and Relative Hypoxia on Post-extraction Socket Wound Healing: A Clinical Pilot Study

**Samuel Ebele Udeabor^{1*}, Muhannad Abdulrhman Halwani¹,
Saad Awadh Alqahtani¹, Saif Ahmed Alshaiki¹,
Amer Mohammed Alqahtani¹ and Saad Mohammed Alqahtani²**

¹Department of Oral and Maxillofacial Surgery, College of Dentistry, King Khalid University, Abha, Saudi Arabia.

²Department of Periodontics and Community Dental Sciences, College of Dentistry, King Khalid University, Abha, Saudi Arabia.

Authors' contributions

This work was carried out in collaboration between all authors. Authors SEU, MAH, Saad Awadh Alqahtani, Saif Ahmed Alshaiki, AMA and SMA designed the study. Author SEU performed the statistical analysis, wrote the protocol and wrote the first draft of the manuscript. Authors MAH, Saad Awadh Alqahtani, Saif Ahmed Alshaiki and AMA managed the analyses of the study. Authors SEU and MAH managed the literature searches. All authors read and approved the final manuscript.

Article Information

DOI: 10.9734/IJTDH/2017/36105

Editor(s):

(1) Jorge Paredes Vieyra, Universidad Autonoma De Baja California, Campus Tijuana, Mexico.

Reviewers:

(1) Mehmet Yaltirik, Istanbul Universty, Turkey.

(2) Rucha Shah, Bapuji Dental College & Hospital, Rajiv Gandhi University, India.

(3) Lauritano Dorina, University of Milan-Bicocca, Italy.

Complete Peer review History: <http://www.sciencedomain.org/review-history/20742>

Original Research Article

Received 12th August 2017
Accepted 25th August 2017
Published 30th August 2017

ABSTRACT

Background: Prolonged hypoxia is known to delay wound healing and in places of high altitudes, hypoxia is a major physiologic challenge. It is however yet to be seen if relative hypoxia in high altitude areas influences intraoral wound healing.

Aim: A prospective study aimed to evaluate the clinical pattern of healing of post-extraction socket wound following simple extraction in an established high altitude location.

Methodology: Thirty-one patients referred to oral surgery clinic for simple (intra-alveolar) exodontia were included in this study. The patients' bio data, indications for extraction and the tooth or teeth to

*Corresponding author's Email: seudeabor@kku.edu.sa; samudeabor@yahoo.com

be extracted were documented on the day of treatment. Simple extractions were performed and patients given post-operative instructions without antibiotics prescription. They were subsequently assessed on days 3 and 7 post-extraction for alveoli wound healing. Data recorded were: presence or absence of pain, day of pain onset, duration of pain, type of healing complication and body temperature.

Results: Fifty-one extraction sockets were evaluated for alveoli healing during the course of the study. The mean age of the patients was 42.84 ± 12.8 years and caries was the commonest indications for extraction. Out of these, 39 (76%) healed uneventfully, whereas 12 (24%) developed healing complications. Alveolar osteitis (dry socket) accounted for 9 (18%) and acutely infected alveoli 3 (6%) of the complications. Posterior teeth have the highest incidence of complications (67%). Pain in patients with alveolar osteitis lasted for more than 5 days whereas acutely infected alveoli presented with only mild pain, which lasted for not more than 3 days.

Conclusion: Uneventful healing occurred in most of the alveoli assessed. However, this was lower than what has been previously reported in the literatures. In addition, the 18% incidence of dry socket recorded in our study far exceeded what other previous studies observed in lowland regions. We can therefore conclude from this study that more complications of alveolar healing are more likely from high altitude areas.

Keywords: Altitude; relative hypoxia; extraction socket wound healing.

1. INTRODUCTION

Healing of extraction sockets is well reported in the literature [1-5]. This involves 5 overlapping stages as described by Amler [1]. There is an initial formation of clot that fills the socket, followed by replacement of the clot with healthy granulation tissue; this in turn is replaced by connective tissue in the third stage. Bone formation begins in the fourth stage and then the regeneration of epithelium to finally close the socket in the final stage of healing between 24 and 35 days after extraction. This normal healing progression can be disturbed at any of the stages resulting in various complications [1,2].

Wound healing in general is influenced by both local and systemic factors [6]. Among the local factors, it is reported that the initial hypoxia (low oxygen availability) that occurs after injury is known to trigger wound healing, however, prolonged hypoxia on the other hand delays wound healing [7,8]. In areas and locations of high altitude, hypoxia is the main physiologic challenge [9], and people inhabiting such places inhale low fractional inspired oxygen tension, which may lead to hypoxemia [10].

Abha, a city located in Aseer province of Saudi Arabia is situated on Aseer Mountains at an altitude of 2800 - 3150 m above sea level making it one of the highest inhabited plateaus in Saudi Arabia [11]. It is therefore designated as a high altitude area [11,12].

Tooth extraction is undoubtedly the commonest procedure carried out in oral surgery clinics and uneventful healing of the extraction socket is the

desire of every dental surgeon. The effects of hypoxia on wound healing is well established, however, it remains to be seen if the relative hypoxia as a result of high altitude has any influence on the intra oral healing of extraction sockets.

The present study therefore evaluated the clinical pattern of healing of post-extraction socket wound following simple extraction in an established high altitude location. This would show the effects of altitude and its attendant hypoxia on extraction socket wound healing.

2. MATERIALS AND METHODS

Adult patients (18 years and above) who reside in Abha and visiting the Oral Surgery Clinic of King Khalid University for routine simple extractions were included in this study. Exclusion criteria: patients with impacted teeth; those already taking antibiotics; those with a medical history of debilitating systemic diseases like diabetes mellitus; those on steroid therapy; those with history of radiotherapy to the head and neck regions; and those that have social habits of smoking and alcohol consumption.

After obtaining the patients consents to participate in the study, extractions were performed under local anesthesia with dental forceps and elevators. Post-operative instructions were given to the patients and only analgesics prescribed. They were then evaluated for socket and alveolus healing on days 3 and 7 after extraction. During the evaluation, each patient was assessed for alveolus infection and presence or absence of pain.

Pain felt by the patients for the post-operative period was graded using a 4-point verbal rating scale (VRS) questionnaire: “no pain” (patient experiences no pain); “mild pain” (pain almost unnoticeable); “moderate pain” (noticeable pain but patient can still engage in routine daily activities); “severe pain” (pain very noticeable and disturbs patient’s daily routine) [2].

The alveoli were also evaluated and categorized accordingly into Alveolar Osteitis, Acutely Inflamed Alveolus, Acutely Infected Alveolus and Normal Healing Alveolus.

A questionnaire containing the above-mentioned items was completed for each patient on the various days of evaluation. The data generated were then analyzed statistically using Microsoft Excel package.

3. RESULTS

Thirty-one patients with a total of 51 extractions were seen during the course of this study. These were patients attending the outpatient oral surgery clinic of King Khalid University Hospital Abha, Saudi Arabia. The mean age of the patients was 42.84 ± 12.8 years with an age range of 18 – 75 years. Most of the patients (37%) were in the 41 – 50 years age range (Fig. 1).

Dental caries was the major indication for extraction accounting for 57% (29 extractions) of the cases seen and was followed by retained/remaining roots (33%), which is also one of the sequelae of dental caries (Fig. 2).

The extraction sockets were assessed for healing and out of the 51 extraction sites, 39 (76%) healed uneventfully, whereas 12 (24%) developed healing complications. Alveolar osteitis (dry socket) accounted for 9 (18%) and acutely infected alveoli 3 (6%) of the complications (Fig. 3). Considering the complications alone, Alveolar osteitis constituted 75% of all the complications and acutely infected alveoli the remaining 25%.

The distribution of the healing complications according to the tooth types is shown in Table 1 with molars being the most affected (42%).

3.1 Normal Healing Alveoli

Thirty-nine post extraction sockets healed without complications. Out of these, 67% (26 alveoli) reported “no pain” throughout the 7 days follow up period. Nine (23%) experienced mild pain, 2 (5%) had moderate pain and 2 (5%) severe pain. None of these pain experiences exceeded the third day post extraction.

3.2 Alveolar Osteitis (Dry Socket)

Nine alveoli developed dry socket and the mean age of patients with this complication was 49 ± 2.5 years. Out of these alveoli, 7 (78%) had mild pain, whereas 1 (11%) each had moderate and severe pain. Onset of pain was in the second post extraction day and the pain lasted for a minimum of 5 days. Apart from pain, other clinical features seen were disintegrated clot in the socket, empty socket in some cases and foul smell.

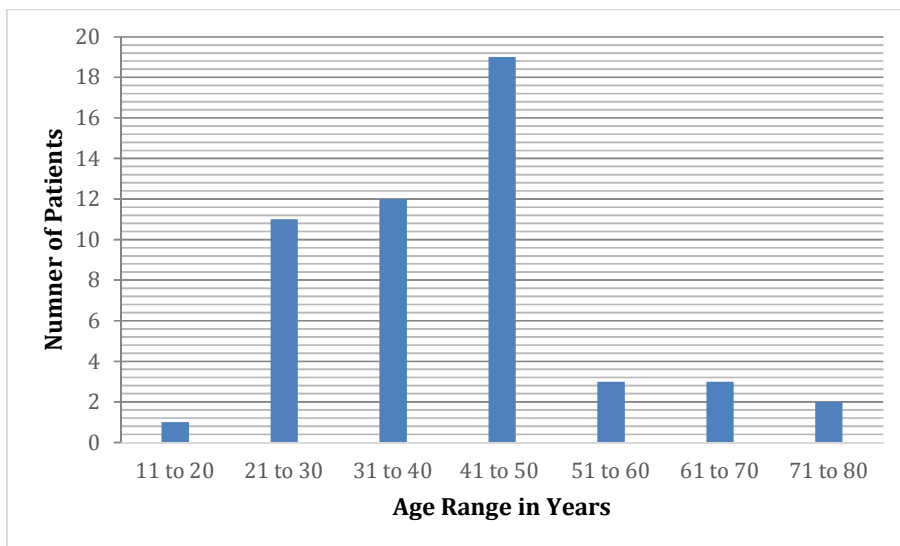


Fig. 1. Age range of patients in the study

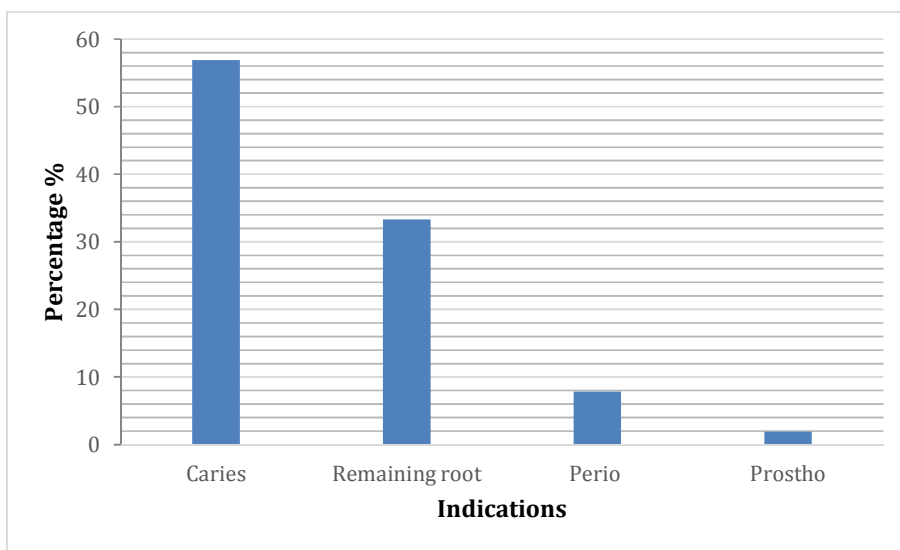


Fig. 2. Indications for extraction

*Key – [Perio: Periodontal disease; Prosthodontics: Prosthetic Reasons]

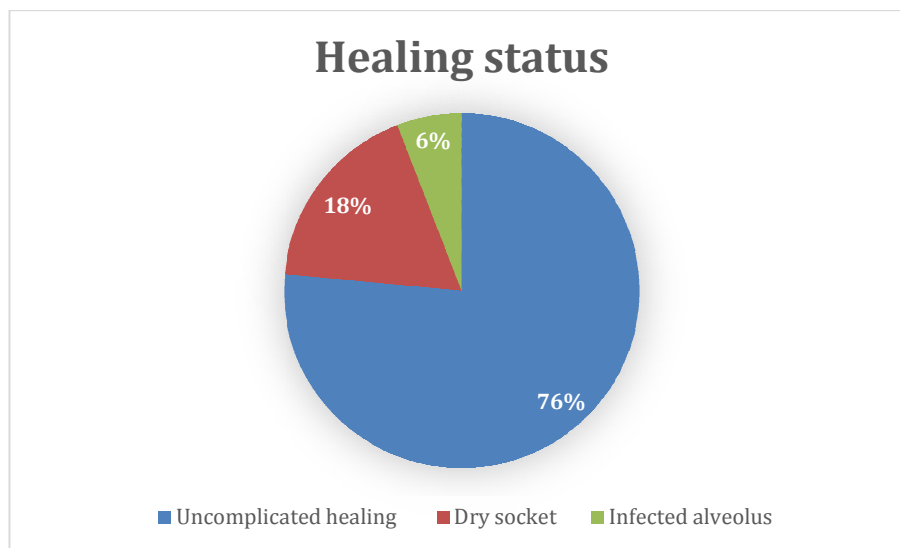


Fig. 3. Healing status in the extraction alveoli

Table 1. Socket healing complications and types of teeth involved

	Socket healing complications			Total (%)
	Dry socket	Infected socket	Inflamed socket	
Incisors	2	0	0	2 (16.67)
Canine	2	0	0	2 (16.67)
Pre Molars	3	0	0	3 (25.00)
Molars	2	3	0	5 (41.67)
Total	9	3	0	12 (100)

3.3 Acutely Infected Alveoli

Only 3 (25%) of the cases had this complication. They all had mild pain, which started on the first

day post extraction and did not last for more than 3 days. The clinical features seen were exudate and mild soft tissue swelling around the sockets.

4. DISCUSSION

Tooth extraction or exodontia is the commonest dental procedure carried out by Oral Surgeons in the dental offices and the main indication for this procedure is usually dental caries along with its sequelae like retained/remaining roots [2,5]. Proper and adequate healing of the ensuing socket wound is desirable to enhance subsequent procedures like implant placements and other prosthetic rehabilitations [1,13]. Ordinarily, most of the extraction socket wounds heal uneventfully and rapidly too. This is the case with our study, where 76% healed without complications. However, the percentage of uneventful healing recorded from our study is far lower than what had been documented from previous studies carried out in low land areas. Adeyemo et al. [2] reported 89%, whereas Oginni et al. [14] reported about 96% of normal uneventful healing. This implies that the 24% complications observed in this present study, far exceeds what other studies have reported [2,14, 15,16].

Alveolar osteitis (dry socket) is generally believed to be the commonest occurring healing complications post extraction [2]. This assertion is corroborated by our study in which alveolar osteitis constituted 75% of all the complications seen and it also agrees with what has been previously reported [2]. This complication occurred mostly in molars and premolars and the mean age of the affected patients was 49±2.5 years. What is different from our study however, is the incidence of alveolar osteitis, which was 18% of the total number of the extracted teeth. This exceeded the incidence of 8.1% reported by Adeyemo et al. [2] and 4.1% observed by Oginni et al. [14]! This then raises the question as to what could have been responsible for such a high incidence of alveolar osteitis in our region?

Wound healing is influenced by a host of factors ranging from local to systemic and also intrinsic and extrinsic factors [6-8]. In this present study, we tried to exclude patients with some of the factors that could alter the extraction socket healing like alcohol consumption, tobacco use, debilitating systemic diseases, radiotherapy to the head and neck region, and immune lowering drugs (e.g. steroids) [17-20]. High levels of infection control measures were also adopted during the tooth extraction procedures to control for some of the extrinsic factors that could influence healing.

With these factors eliminated, one can therefore assume that another major factor that could possibly influence the progress of the socket wound healing is relative hypoxia, which is peculiar to our environment because of its high altitude location. Our city Abha, is designated as a high altitude area because it is situated on Aseer mountains at an altitude of 2,800 to 3150 meters above sea level [11,12].

People that inhabit areas of high altitudes are known to inhale low fractional inspired oxygen tension, which may lead to hypoxia [10]. It has been established also that prolonged hypoxia in turn delays wound healing generally [7,8].

We cannot however attribute all the results of this study to the effects of hypoxia, as there are other confounding factors that may have likely influenced the healing process also. Patient's inability to follow post-operative instructions and observe good oral hygiene principles are but a few other factors that could interrupt socket healing thereby leading to various complications.

In order to minimize the effects of hypoxia on the healing of extraction sockets in high altitude areas, our recommendations are that the Dental Surgeon should observe strict infection control measures and apply the principles of atraumatic extraction during the procedure. Additionally, either autologous platelet-rich fibrin (PRF) or platelet-rich plasma (PRP) should be applied to the extraction sockets as they are proven adjuncts that aid intraoral wound healing [21,22].

We did not observe other complications of extraction sockets healing like acutely inflamed alveoli, necrotizing osteitis and fibrous healing as documented by other authors [1,2]. This may be due to the short duration of our study and the small number of patients seen.

5. CONCLUSION

Uneventful healing occurred in most of the alveoli assessed in this study. However, this was lower than what has been previously reported in the literatures. In addition, the 18% incidence of dry socket recorded in our study far exceeded what other previous studies observed in lowland regions. We can therefore conclude from the present study that complications of extraction socket healing are more likely to occur in patients inhabiting high altitude areas.

6. LIMITATIONS

The number of patients assessed in this study was few and for a short duration also. In order to draw reasonable conclusions, more patients need to be included and the study done for a longer period of time.

CONSENT AND ETHICAL APPROVAL

The Scientific Research Committee of the College of Dentistry, King Khalid University Abha, Saudi Arabia, approved this study. Each of the patients that participated in the study also signed the informed consent form prior to the treatment.

COMPETING INTERESTS

Authors have declared that no competing interests exist.

REFERENCES

1. Amler MH. Disturbed healing of extraction wounds. *J Oral Implantol.* 1999;25(3):179-84.
2. Adeyemo WL, Ladeinde AL, Ogunlewe MO. Clinical evaluation of post-extraction site wound healing. *J Contemp Dent Pract.* 2006;7(3):40-9.
3. Ahn JJ, Shin HI. Bone tissue formation in extraction sockets from sites with advanced periodontal disease: A histomorphometric study in humans. *Int J Oral Maxillofac Implants.* 2008;23(6): 1133-8.
4. Cohen N, Cohen-Levy J. Healing processes following tooth extraction in orthodontic cases. *J Dentofacial Anom Orthod.* 2014;17:304.
DOI: 10.1051/odfen/2014006
5. Steiner GG, Francis W, Burrell R, Kallet MP, Steiner DM, Macias R. The healing socket and socket regeneration. *Compend Contin Educ Dent.* 2008;29(2):114-6, 118, 120-4. Passim
6. Guo S, Dipietro LA. Factors affecting wound healing. *J Dent Res.* 2010;89(3): 219-29.
7. Rodriguez PG, Felix FN, Woodley DT, Shim EK. The role of oxygen in wound healing: A review of the literature. *Dematol Surg.* 2008;34(9):1159-69.
8. Chambers AC, Leaper DJ. Role of oxygen in wound healing: A review of evidence. *J Wound Care.* 2011;20(4):160-4.
9. Yan Y, Shi Y, Wang C, Guo P, Wang J, Zhang CY, Zhang C. Influence of high altitude hypoxic environment on human plasma microRNA profiles. *Sci Rep.* 2015; 5:15156.
DOI: 10.1038/srep15156
10. Grocott M, Montgomery H, Vercueil A. High-altitude physiology and pathophysiology: Implication and relevance for intensive care medicine. *Crit Care.* 2007; 11(1): 203.
DOI: 10.1186/cc5142
11. Al-Hashem FH. The effects of high altitude on blood hormones in male westar rats in south western Saudi Arabia. *Am J Environ Sci.* 2010;6(3):268-74.
12. Al-Shehri MA, Abolfotouh MA, Dalak MA, Nwoye LD. Birth anthropometric parameters in high and low altitude areas of southwest Saudi Arabia. *Saudi Med J.* 2005;26(4):560-5.
13. De Coster P, Browaeys H, De Bruyn H. Healing of extraction sockets filled with BoneCeramic® prior to implant placement: Preliminary histological findings. *Clin Implant Dent Relat Res.* 2011;13(1): 34-45.
14. Oginni FO, Fatusi OA, Alagbe AO. A clinical investigation of dry alveolus in a Nigerian teaching hospital. *J Oral Maxillofac Surg.* 2003;61:871-6.
15. Cheung LK, Chowe LK, Tsang MH, Tung LK. An evaluation of complications following dental extractions using either sterile or clean gloves. *Int J Oral Maxillofac Surg.* 2001;30:550-4.
16. Jaafar N, Nor GM. The prevalence of post extraction complications in an out patient dental clinic in Kuala Lumpur Malaysia a retrospective survey. *Singapore Dent J.* 2000;23:24-8.
17. Pinto JR, Bosco AF, Okamoto T, Guerra JB, Piza IG. Effects of nicotine on the healing of extraction sockets in rats. A histological study. *Braz Dent J.* 2001;12(1): 3-9.
18. Devlin H, Garland H, Sloan P. Healing of tooth extraction sockets in experimental diabetes mellitus. *J Oral Maxillofac Surg.* 1996;54(9):1087-91.
19. Kim JH, Susin C, Min JH, Suh HY, Sang EJ, Ku Y, et al. Extraction sockets: Erratic healing impending factors. *J Clin Periodontol.* 2014;41:80-5.
20. Wang AS, Armstrong EJ, Armstrong AW. Corticosteroids and wound healing: Clinical

- considerations in the perioperative period. Am J Surg. 2013;206(3):410-7.
21. Al-Hamed FS, Tawfik MA, Abdelfadil E. Clinical effects of platelet-rich fibrin (PRF) following surgical extraction of lower third molar. Saudi J Dent Res. 2017;8(1-2): 19-25.
22. Albanese A, Licata ME, Polizzi B, Campisi G. Platelet-rich plasma (PRP) in dental and oral surgery: From the wound healing to bone regeneration. Immun Ageing. 2013; 10:23.
DOI: 10.1186/1742-4933-10-23

© 2017 Udeabor et al.; This is an Open Access article distributed under the terms of the Creative Commons Attribution License (<http://creativecommons.org/licenses/by/4.0>), which permits unrestricted use, distribution, and reproduction in any medium, provided the original work is properly cited.

Peer-review history:
The peer review history for this paper can be accessed here:
<http://sciencedomain.org/review-history/20742>