



## **International Journal of Medical and Pharmaceutical Case Reports**

**10(1): 1-6, 2017; Article no.IJMPCR.36322**  
**ISSN: 2394-109X, NLM ID: 101648033**

# **Gingival Overgrowth Associated with Phenytoin Therapy: Report of a Case**

**Kavita Nagar<sup>1\*</sup>, R. Poornima<sup>1</sup>, G. P. Sujatha<sup>1</sup> and L. Ashok<sup>1</sup>**

<sup>1</sup>*Department of Oral Medicine and Radiology, Bapuji Dental College and Hospital, Davangere,  
Karnataka, India.*

### **Authors' contributions**

*This work was carried out in collaboration between all authors. Author KN did diagnosis, acquisition of data, conception, and designing. Author RP did diagnosis, drafting and revised the manuscript. Authors GPS and LA revised and had done final approval of the manuscript. All authors read and approved the final manuscript.*

### **Article Information**

DOI: 10.9734/IJMPCR/2017/36322

#### Editor(s):

(1) Manuel Marques Ferreira, Area of Dentistry, University of Coimbra, Portugal.

#### Reviewers:

(1) B. C. Ephraim-Emmanuel, Bayelsa State College of Health Technology, Nigeria.

(2) Shamimul Hasan, Jamia Millia Islamic, New Delhi, India.

Complete Peer review History: <http://www.sciencedomain.org/review-history/21036>

**Case Study**

**Received 23<sup>rd</sup> August 2017**  
**Accepted 11<sup>th</sup> September 2017**  
**Published 16<sup>th</sup> September 2017**

## **ABSTRACT**

Gingival overgrowth (also called gingival hyperplasia, or gingival hypertrophy) refers to an increase in the size of the gingiva. It is seen as an adverse effect of drugs such as anticonvulsants, immunosuppressants, and calcium channel blockers. Phenytoin is a commonly used anticonvulsant for treatment of epilepsy. Phenytoin-induced gingival overgrowth is a well-known and frequently reported gingival disease. The pathogenesis of phenytoin-induced gingival overgrowth is multifactorial. The gingival enlargement is noticed first in the interdental papilla region which gradually coalesce extending along the labial, lingual, and coronal aspect. In severe cases, it may cover the entire anatomic crowns of teeth. These changes are most apparent in the anterior part of the mouth. The gingiva appears dense, resilient, and stippled, giving a beaded appearance. The color ranges from pink to a deep bluish red depending on the amount of inflammatory infiltrate present in the gingival tissues and secondary inflammation by local factors may induce edema, ulcerations and bleeding. Providing suitable drug substitution often brings about the partial or complete regression of the lesion and can be considered after a physician consult. However, in

\*Corresponding author: E-mail: kavitanagar0789@gmail.com;

severe enlargements surgical gingival resection is required. Hereby, a case of phenytoin induced gingival overgrowth is reported which showed a substantial reduction in gingival growth after substitution of phenytoin therapy by phenobarbitone for treatment of epilepsy.

**Keywords:** *Gingival enlargement; phenytoin-induced gingival overgrowth (PIGO).*

## 1. INTRODUCTION

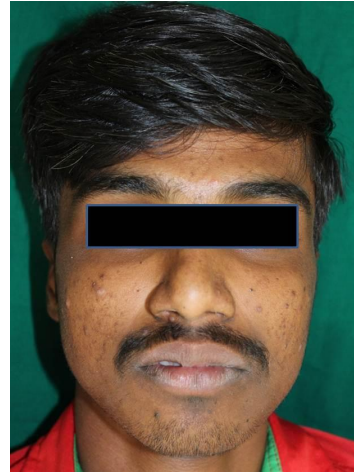
Gingival overgrowth, also called gingival hyperplasia, or gingival hypertrophy, refers to an increase in the size of the gingiva. It is one of the infrequent findings among the gingival diseases. There are multiple etiologic factors for gingival enlargement like inflammation, drugs, various systemic diseases, and neoplasia. Drug-induced gingival hyperplasia is a noted side effect of calcineurin inhibitors such as cyclosporine (CsA) and tacrolimus (TAC), anti-convulsant/anti-seizure drugs such as phenytoin (PHT), and calcium channel blocking agents (CCBAs) such as amlodipine and nifedipine [1]. Amongst these phenytoin induced gingival overgrowth is most commonly encountered. Phenytoin is a commonly prescribed medication for the treatment of patients with epilepsy [2].

## 2. CASE PRESENTATION

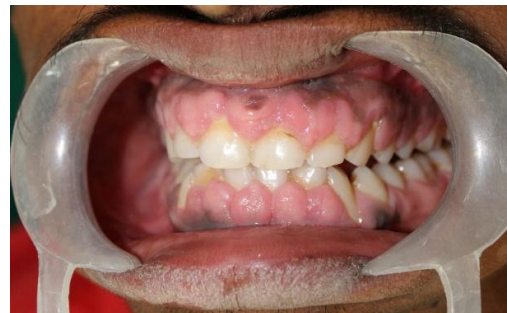A 22 years old male patient (Fig. 1) reported to the department of Oral Medicine and Radiology with a chief complaint of swelling of upper and lower front gums since 4 months. History of present illness revealed that swelling was insidious in onset, gradually progressing, initially smaller in size which progressed to the current size. Past medical history revealed that patient was epileptic since 5 years and was taking tab Eptoin 100 mg – 3 tablets daily at bedtime. The patient did not report any triggering factors.

Intraoral examination revealed gingival overgrowth of maxillary and mandibular anterior gingiva, involving marginal, attached and interdental gingiva, extending upto middle third of crowns of anterior teeth, pale pink in color, lobulated in appearance, stippling was evident on interdental papillae as shown in Fig. 2. Gingival overgrowth was non-tender and firm in consistency with no bleeding on probing.

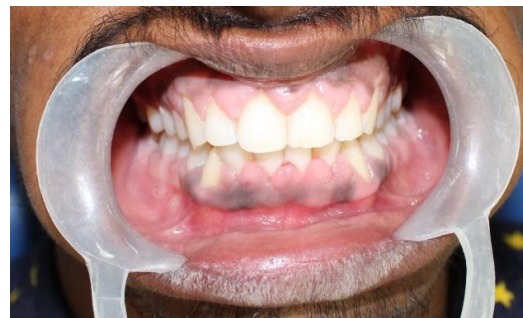Diagnosis of phenytoin induced gingival overgrowth was made. Patient was referred to the physician wherein his medication was changed to phenobarbitone 60 mg once daily. A significant reduction in gingival overgrowth was noted after a follow up of 1 month after change of medication as shown in Figs. 3 and 4.



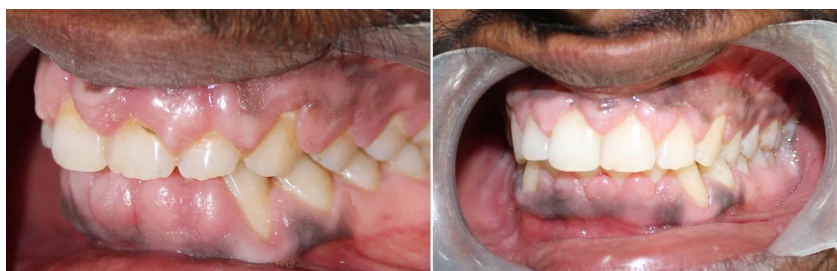**Fig. 1. Clinical photograph showing patient's profile**



**Fig. 2. Intraoral photograph showing enlarged gingiva in maxillary and mandibular anterior teeth region**



**Fig. 3. Reduction in gingival enlargement seen after 1 month follow up, after substitution of phenytoin**



**Fig. 4. Intraoral photographs before and 1 month after substitution of phenytoin showing marked reduction in gingival enlargement**

### 3. DISCUSSION

Gingival enlargement is a known side effect of anticonvulsants, immunosuppressants and calcium channel blockers. Phenytoin, carbamazepine and sodium valproate are among the more commonly prescribed first line of drugs for the control of epilepsy [3]. Despite tremendous advances in the management of epilepsy in the recent decade, the anti-epileptic drug phenytoin still remains the prime drug in the management of epileptic patients in India [4]. Thus, phenytoin-induced gingival enlargement is the most prevalent, affecting approximately 50% of patients who use the drug for longer than 3 months. Patient in our case had taken phenytoin for about five years.

Phenytoin-Induced Gingival Overgrowth (PIGO) is commonly seen in older children and young adults, being exceptionally rare in edentulous subjects. Both genders have been reported to be equally susceptible to phenytoin induced gingival enlargement in the literature [5]. These may create speech, mastication, tooth eruption, and aesthetic problems. The first sign of enlargement is noticed in the inter-dental papilla region. Gradually, interdental papilla coalesces

extending along the labial, lingual, and coronal aspect. In severe cases it may cover the entire anatomic crowns of teeth. The gingiva appears dense, resilient, and stippled. The effects are most apparent in the anterior part of mouth. Similar features were seen in our case also. The overgrowth takes 2–3 months to become noticeable and can take 12–18 months to reach its maximal severity.

The first case was reported by Kimball in 1939 in which hyperplasia of gums was noted during treatment of epileptic patients with sodium diphenyl hydantoinate (Dilantin) [6]. The extent of inflammation, fibrosis and cellularity depends on the duration, dose of the drug; on the quality of oral hygiene; and on individual susceptibility that stems from genetic factors and environmental influences. Gingival overgrowth can also lead to the formation of pockets with potential accumulation of debris, leading to poor dental hygiene, halitosis, and gingival bleeding.

The earliest classification was given by Kapur and Girgis, which was modified by other authors. The gingival changes associated with Phenytoin can be graded as follows –

According to Angelopoulos and Goaz [7]	
Grade	Definition
0	No hyperplasia, normal gingiva
I	Hyperplastic gingiva covering the cervical third or less of the anatomic crowns of anterior teeth
II	Hyperplastic gingiva extending anywhere in the middle third of the anatomic crowns of anterior teeth
III	Hyperplastic gingiva covering more than two-thirds of the anatomic crowns of anterior teeth

According to Addy's modification of Harris and Evalt rating [8]	
Grade	Definition
0	No hyperplasia
I	Minimal: increased density of gingiva with marked stippling and granular appearance
II	Moderate: increase in the size of papilla or rolled gingival margins
III	Severe: profound thickening of gingiva covering a large percentage of the clinical crown

### 3.1 Pathogenesis

The mechanisms of development of PIGO are multiple and complex including alterations at the cellular and molecular level involving fibroblasts, cytokines, growth factors, and genetic susceptibility as represented by Fig. 5. The etiopathogenesis of phenytoin induced gingival enlargement is still not clearly understood, however, many studies indicate its multifactorial etiology including oral hygiene status of the affected epileptic patients.

The accumulation of proteins in ECM, particularly collagen, may occur due to an imbalance between the synthesis and the degradation of ECM, being the possible cause of the GO. These drugs induce a decrease in the  $Ca^{2+}$  cell influx (due to changes in the sodium-calcium exchange) leading to a reduction in the uptake of folic acid, thus limiting the production of active collagenase [9].

In 2005, Kato et al. showed that the gene expression of MMP-1, 2, and 3 was reduced by phenytoin administration, while the TIMP-1 mRNA was markedly augmented [10]. In accordance, macrophages pretreated with phenytoin and then exposed to LPS had lower production of MMPs than not treated controls [11]. Therefore, this reduction of MMPs is believed to influence the PIGO development.

The possible role of phenytoin on fibroblasts growth and death has also been investigated. The study of Kantarci et al. demonstrated that fibroblast apoptosis is decreased in GO, and that this decrease may contribute to fibrosis, particularly in PGO [12].

### 3.2 Role of Inflammation and Growth Factors

Fibrosis usually results from chronic inflammation—in which inflammation, tissue remodeling and repair processes occur simultaneously [13]. The repair process involves two stages: a regenerative phase and a phase known as fibrosis, in which connective tissues replace normal parenchyma. This phase can become harmful if not properly controlled, resulting in an excessive deposition of ECM [14].

Some cytokines and growth factors were found in higher levels in gingival overgrown tissues, including interleukin-6 (IL-6), IL-1, platelet derived growth factor- $\beta$  (PDGF- $\beta$ ), fibroblast growth factor-2 (FGF-2), transforming growth factor- $\beta$  (TGF- $\beta$ ) and connective tissue growth factor (CTGF). Phenytoin also increases the production of IL-6 and IL-8 by fibroblasts [15]. IL-6 is capable of activating the proliferation of T and B cells, and it has been associated with fibrosis in various organs. The increase of IL-6 levels seems to involve the cyclooxygenase-2 (COX-2) pathway.

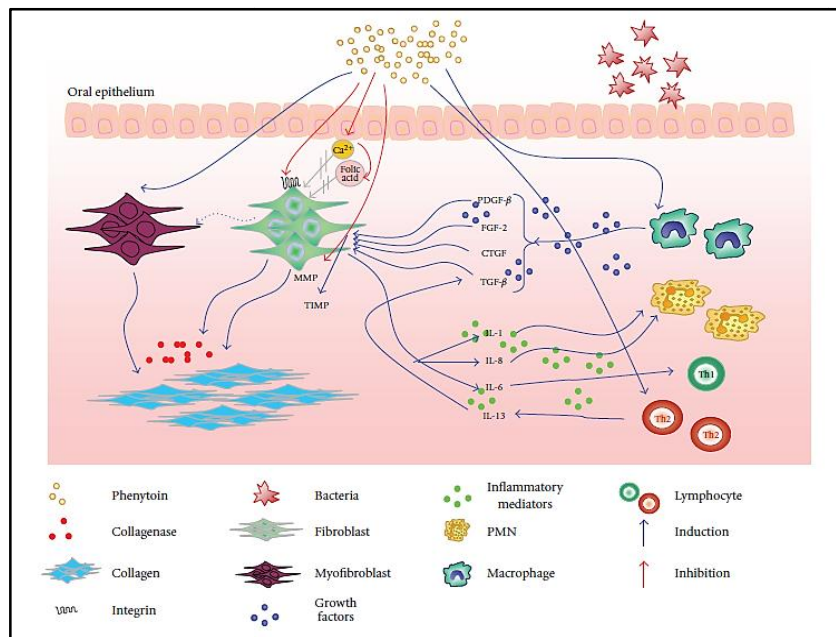


Fig. 5. Pathogenesis of phenytoin-induced gingival overgrowth [19]

### 3.3 Genetic Susceptibility

Pharmacogenetic influences on drug metabolism have been widely reviewed and gene polymorphism of cytochrome P450 2C19 appeared to be responsible for much of the interindividual variability on drug elimination [16]. Polymorphisms in CYP2C9 were reported and particularly the 2C9\*3 polymorphism has been suggested to exert great influence on the metabolism of phenytoin, so it was hypothesized to be a candidate gene for prevention and early diagnosis of the GO severity [17]. Soga et al. showed in a study with 28 patients taking phenytoin that those who had the expression of the polymorphism CYP2C9\*3 had higher serum concentrations of phenytoin [18].

Suitable drug substitution often brings about the partial or complete regression of the lesion and can be considered after a physician consult. The lower grades of PIGO usually reverse after a mean duration of 4 months on stopping Phenytoin therapy. In our case, there was a significant reduction in gingival enlargement after one month, after the medication was changed. Severe grades of PIGO requires gingivectomy to establish normal contour of the gingiva, but it may be complicated by recurrence on continued exposure to phenytoin. Scalpel gingivectomy, flap surgery, electrosurgery and laser gingivectomy are the surgical modalities frequently used to manage severe overgrowths.

Chlorhexidine mouth rinse was found to have some value in preventing PIGO in post-operative patients. The use of folic acid as an adjuvant to phenytoin therapy in the prevention of phenytoin-induced gingival enlargement can be considered. [20].

### CONCLUSION

Gingival overgrowth is one of the most common side effects associated with the administration of phenytoin, the most frequently used antiepileptic drug. It characterized by enlargement of interdental papillae in maxillary and mandibular anterior gingiva especially buccal aspect, giving it a pearly or beaded appearance. This may get secondarily inflamed owing to local factors. Substitution of the drug with physician's consultation is necessary. Severe cases may require surgical intervention. Patient's compliance for maintenance of oral hygiene is required to prevent further complications.

### CONSENT

As per international standard or university standard, patient's written consent has been collected and preserved by the author(s).

### ETHICAL APPROVAL

It is not applicable.

### COMPETING INTERESTS

Authors have declared that no competing interests exist.

### REFERENCES

1. Gurgel BC, de Moraes CR, da Rocha-Neto PC, Dantas EM, Pinto LP, Costa Ade L. Phenytoin-induced gingival overgrowth management with periodontal treatment. *Braz Dent J.* 2015;26(1):39-43.
2. Brown R, Arany P. Mechanism of drug-induced gingival overgrowth revisited: A unifying hypothesis. *Oral diseases.* 2015;21(1):e51-e61.
3. Bharti V, Bansal C. Drug-induced gingival overgrowth: The nemesis of gingiva unraveled. *J Indian Soc Periodontol.* 2013;17(2):182-87. DOI: 10.4103/0972-124X.113066 [PMCID: PMC3713748]
4. Scheinfeld N. Phenytoin in cutaneous medicine: Its uses, mechanisms and side effects. *Dermatol Online J.* 2003;9:6. [PMID: 12952753]
5. Brunet L, Miranda J, Farré M, et al. Gingival enlargement induced by drugs. *Drug Saf.* 1996;15:219-31.
6. Kimball OP. The treatment of epilepsy with sodium diphenylhydantoinate. *JAMA.* 1939;112:1244.
7. Angelpoulous AP, Goaz PW. Incidence of diphenylhydantoin gingival hyperplasia. *Oral Surg Oral Med Oral Pathol.* 1972;34:898-906.
8. Perlik F, Kolinova M, Zvarova J, Patzelova V. Phenytoin as a risk factor in gingival hyperplasia. *Ther Drug Monit.* 1995;17:445-8.
9. Spolidorio LC, Gonzaga HF, Spolidorio DM. Quantitative analysis of gingival tissues of rats treated with phenytoin and cyclosporine. *Pesquisa Odontológica Brasileira.* 2000;14(4):327-33.
10. Kato T, Okahashi N, Kawai S, Kato T, Inaba H, Morisaki I, Amano A. Impaired



- degradation of matrix collagen in human gingival fibroblasts by the antiepileptic drug phenytoin. *Journal of Periodontology*. 2005;76(6):941-50.
11. Serra R, Al-saidi AG, Angelov N, Nares S. Suppression of LPS-induced matrix-metalloproteinase responses in macrophages exposed to phenytoin and its metabolite, 5-(p-hydroxyphenyl)-, 5-phenylhydantoin. *Journal of Inflammation*. 2010;7(1):48.
  12. Kantarci A, Augustín P, Firatli E, Sheff MC, Hasturk H, Graves DT, Trackman PC. Apoptosis in gingival overgrowth tissues. *Journal of Dental Research*. 2007;86(9): 888-92.
  13. Wynn TA. Common and unique mechanisms regulate fibrosis in various fibroproliferative diseases. *Journal of Clinical Investigation*. 2007;117(3):524. DOI: 10.1172/JCI31487 [PMCID: PMC1804380]
  14. Wynn TA. Cellular and molecular mechanisms of fibrosis. *The Journal of Pathology*. 2008;214(2):199-210. DOI: 10.1002/path.2277
  15. Suzuki AM, Yoshimura A, Ozaki Y, Kaneko T, Hara Y. Cyclosporin A and phenytoin modulate inflammatory responses. *Journal of Dental Research*. 2009;88(12):1131-6.
  16. A Bergen DC. Pharmacokinetics of phenytoin: Reminders and discoveries. *Epilepsy Currents*. 2009;9(4):102-4. DOI: 10.1111/j.1535-7511.2009.01307.x
  17. Veronese ME, Mackenzie PI, Doecke CJ, McManus ME, Miners JO, Birkett DJ. Tolbutamide and phenytoin hydroxylations by cDNA-expressed human liver cytochrome P450C9. *Biochemical and Biophysical Research Communications*. 1991;175(3):1112-8. DOI: 10.1016/0006-291X(91)91680-B
  18. Soga Y, Nishimura F, Ohtsuka Y, Araki H, Iwamoto Y, Naruishi H, Shiomi N, Kobayashi Y, Takashiba S, Shimizu K, Gomita Y. CYP2C polymorphisms, phenytoin metabolism and gingival overgrowth in epileptic subjects. *Life Sciences*. 2004;74(7):827-34. PMID: 14659971
  19. Corrêa JD, Queiroz-Junior CM, Costa JE, Teixeira AL, Silva TA. Phenytoin-induced gingival overgrowth: A review of the molecular, immune, and inflammatory features. *ISRN Dentistry*; 2011. DOI: 10.5402/2011/497850 [PMCID: PMC3168966]
  20. Nayyar AS, Khan M, Vijayalakshmi KR, et al. Phenytoin, folic acid and gingival enlargement: Breaking myths. *Contemporary Clinical Dentistry*. 2014; 5(1):59-66. DOI:10.4103/0976-237X.128666 [PMCID: PMC4012119]

© 2017 Nagar et al.; This is an Open Access article distributed under the terms of the Creative Commons Attribution License (<http://creativecommons.org/licenses/by/4.0>), which permits unrestricted use, distribution, and reproduction in any medium, provided the original work is properly cited.

*Peer-review history:*  
The peer review history for this paper can be accessed here:  
<http://sciedomain.org/review-history/21036>