



International Journal of Medical and Pharmaceutical Case Reports

10(1): 1-4, 2017; Article no.IJMPCR.36692
ISSN: 2394-109X, NLM ID: 101648033

Mucinous Neoplasm of the Appendix – An Incidental Histopathologic Finding after Appendectomy Due to the Acute Appendicitis – Case Report

Jurij Janež^{1*} and Klemen Mihelčič²

¹Department of Abdominal Surgery, University Medical Centre Ljubljana, Zaloška Cesta 7,
1525 Ljubljana, Slovenia.

²Medical Faculty, University of Ljubljana, Vrazov Trg 2, 1104 Ljubljana, Slovenia.

Authors' contributions

This work was carried out in collaboration between both authors. Author JJ designed the study, performed the statistical analysis, wrote the protocol and wrote the first draft of the manuscript. Author KM managed the analyses of the study and the literature searches. Both authors read and approved the final manuscript.

Article Information

DOI: 10.9734/IJMPCR/2017/36692

Editor(s):

- (1) Erich Cosmi, Director of Maternal and Fetal Medicine Unit, Department of Woman and Child Health, University of Padua School of Medicine, Padua, Italy.
(2) Nurhan Cucer, Medical Biology Department, Faculty of Medicine, Erciyes University, Turkey.

Reviewers:

- (1) Einar Arnbjörnsson, Lund University, Sweden.
(2) Waseem Mehmood Nizamani, KSA.
(3) Fábio Campos, University of São Paulo, Brazil.

Complete Peer review History: <http://www.sciencedomain.org/review-history/21337>

Case Study

Received 9th September 2017

Accepted 6th October 2017

Published 11th October 2017

ABSTRACT

This paper presented a case of a male patient, who was referred from the gastroenterology unit to our department for an emergency surgery due to an acute appendicitis with suspected perforation as shown on the abdominal computed tomography scan. The patient underwent a laparoscopic appendectomy. Samples of the appendix were sent to the pathology department and the histopathological diagnosis was a low-grade appendiceal mucinous neoplasia with perforation.

Keywords: Acute appendicitis; mucinous neoplasm; incidental finding; surgery.

*Corresponding author: E-mail: jurij.janez@gmail.com;

1. INTRODUCTION

Mucinous neoplasms of the appendix are a diverse group [1]. They can be divided into 3 main categories: a) adenoma, b) mucinous neoplasm of uncertain malignant potential or a low-grade appendiceal mucinous neoplasm (LAMN) and c) adenocarcinoma. Clinically, they may present as a right lower abdominal pain mimicking acute appendicitis, an abdominal mass, or pseudomyxoma peritonei [2]. It is important to discover them, as they have the potential to spread to the peritoneum and other viscera [3]. LAMN is rare entity. The prevalence of cystadenoma is reportedly less than 1% of resected appendices [4].

In this paper we present a case of a LAMN diagnosed in the setting of postoperative diagnostics.

2. CASE REPORT

In this report we present a case of a 67-year-old male patient, who was referred to our department from the gastroenterology unit due to severe abdominal pain, lasting for one day. Otherwise he had a liver transplantation in 2011, he also had a mitral and tricuspid insufficiency, stage 3 chronic kidney disease, arterial hypertension and diabetes mellitus type 2. Abdominal CT was performed, showing signs of acute appendicitis with suspected perforation (Fig. 1).

The patient was prepared for an emergency operation and sent to the operating room. He was placed in a supine position and endotracheally intubated under general anesthesia. Perioperative antibiotic prophylaxis with gentamicin and metronidazole was administered. The operative field was prepared in a sterile manner. We made an infraumbilical incision and created a pneumoperitoneum with Veress needle. Then laparoscopy was performed. A local peritonitis in the lower part of abdomen was observed. Appendix was then visualized. It was thickened, gangrenous and perforated in its middle part. The appendix was extracted afterwards. The abdominal cavity was irrigated with saline and the fluid aspirated. An abdominal drain was inserted into the lesser pelvis. The fascia and skin wounds were sutured.

Resection samples of the appendix were sent for the histopathological analysis. The histopathologic report spoke of an acute gangrenous appendicitis with low grade appendiceal mucinous neoplasia (LAMN) with perforation in the area of LAMN. The epithelium of LAMN has been expanding into the superficial part of the muscular layer.

After the surgery he was transferred to the intensive care unit. The rest of the postoperative course was uneventful. On the 6th postoperative day he was discharged from the hospital.

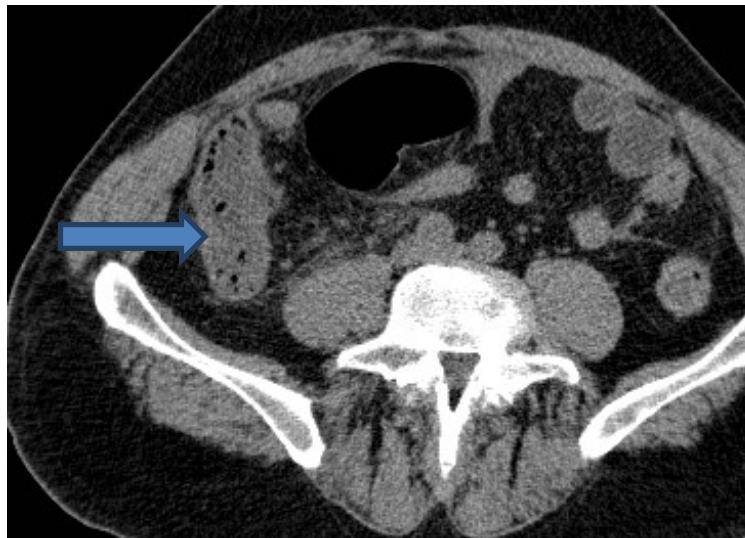


Fig. 1. Abdominal CT with contrast enhancement. The arrow points to an enlarged and thickened appendix with suspected perforation. There is some fluid around the appendix

3. DISCUSSION

Classification and nomenclature of appendiceal mucinous neoplasms is still not uniform and has been a matter of controversy for years. In 2009, Pai et al. proposed a classification based on cytoarchitectural features and extent of disease at presentation to define the categories of appendiceal tumours [5].

Regardless of this fairly recent classification, many pathologists still use the terminology introduced by Misraji in 2003 which divides mucinous neoplasms only into 2 categories: LAMN for all low-grade mucinous tumours of the appendix that lack invasion of the appendiceal wall, that are either confined to the appendix or that have spread to the peritoneum, and adenocarcinoma for tumours with either high-grade cytology and/or invasion [5].

It is also important to keep in mind that appendiceal mucinous neoplasms are associated with an increased incidence of other tumors. The rate of concomitant tumors is reportedly as high as 29%. The most frequent are colon and rectal cancers, followed by epithelial ovarian cancer. Postoperative follow-up colonoscopy, pelvic exams and measuring of CEA level is important. [6].

LAMNs are well-differentiated adenomas that can proliferate outside the appendix in a malignant fashion and are low-grade tumors [1]. They are a rare entity with an incidence ranging from 0.2% to 0.7% of all resected appendixes. Approximately 25% to 50% of LAMNs are incidental findings. Initial presentation can range from asymptomatic to right lower quadrant abdominal pain or a palpable abdominal mass. Differential diagnosis among others include acute appendicitis, diverticulitis, peritoneal carcinomatosis originating from colon cancer, peritoneal mesothelioma, disseminated peritoneal fungal infections or pseudomyxoma peritonei. They are divided into two major classes. LAMN-I is more prevalent among younger people with the tumor usually confined to the lumen of the appendix. It rarely progresses, so only regular 6 month check ups are needed with measurement of tumor markers, CT of the abdomen and pelvis. LAMN-II is usually found in older patients, with mucin also found in the intestinal wall or in the area around the appendix. Recommended treatment for

LAMN-II includes hyperthermic intraperitoneal chemotherapy and surgery with a more aggressive follow-up [7]. Peritoneal dissemination is the most common form of metastasis observed in LAMN and this condition is called pseudomyxoma peritonei (PMP). According to Smeenk et al., a PMP rate of 20 % was observed in patients with LAMN histology [8].

Surgical treatment primarily depends on the histology and also clinical presentation of the mucinous neoplasm. Right hemicolectomy is reserved for invasive adenocarcinomas because of the potential for lymph node metastases [1]. Right hemicolectomy is not always required though as selected tumors can be managed with a minimally invasive surgery [6].

When excising appendiceal mucocoeles it is vital to be very cautious as perforation and spillage of its content can result into the development of PMP [1,7].

Every surgery of mucinous appendiceal neoplasms should include the inspection of the entire abdomen for signs of peritoneal dissemination. If mucin is present then it must be collected and sent for cytology [1].

The 5-year survival for retention cysts and adenomas is 91–100%. According to Misraji et al., in their study of 107 mucinous appendiceal neoplasms, malignant peritoneal disease had 3- and 5-year survival rates of 90% and 44% and a low-grade peritoneal disease was associated with 100% and 86% survival. Ten-year survival in patients with mucinous adenocarcinoma is usually less than 10% [1].

Our patient had a LAMN, without any signs of mucin in the peritoneal cavity. The LAMN was confined only to the appendix, which is a good prognostic factor. The patient is regularly followed after the surgery.

4. CONCLUSION

Mucinous neoplasms of the appendix are rare entity. Most often they are incidental histopathologic findings after appendectomy due to acute appendicitis. It is important to recognize and treat them accordingly because of their malignant potential. The treatment of choice is usually surgery.

CONSENT

As per international standard or university standard, patient's written consent has been collected and preserved by the authors.

ETHICAL APPROVAL

It is not applicable.

COMPETING INTERESTS

Authors have declared that no competing interests exist.

REFERENCES

1. Tirumani SH, Fraser-Hill M, Auer R, Shabana W, Walsh C, Lee F, et al. Mucinous neoplasms of the appendix: A current comprehensive clinicopathologic and imaging review. *Cancer Imaging*. 2013;13(1):14-25.
2. Xiao SY. Mucinous neoplasms of the vermiform appendix. *Surgical Pathology Clinics*. 2010;3(2):395-409.
3. Panarelli NC, Yantiss RK. Mucinous neoplasms of the appendix and peritoneum. *Archives of Pathology & Laboratory Medicine*. 2011;135(10):1261-1268.
4. Lamps LW, Gray GF, Dilday BR, Washington MK. The coexistence of low-grade mucinous neoplasms of the appendix and appendiceal diverticula: A possible role in the pathogenesis of pseudomyxoma peritonei. *Mod Pathol*. 2000;13(5):495-501.
5. Rouzbahman M, Chetty R. Mucinous tumours of appendix and ovary: An overview and evaluation of current practice. *Journal of Clinical Pathology*. 2014;67(3):193-197.
6. Costa V, DeMuro JP. Low-grade appendiceal neoplasm presenting as a volvulus of the cecum. *Gastroenterology Report*. 2013;1(3):207-210.
7. Kapila A, Phemister J, Patel P, Reddy CM, Murthy R, Young MF. An incidental discovery of low-grade appendiceal mucinous neoplasm. *The Permanente Journal*. 2014;18(4):153-154.
8. Foster JM, Sleightholm RL, Wahlmeier S, Loggie B, Sharma P, Patel A. Early identification of DPAM in at-risk low-grade appendiceal mucinous neoplasm patients: a new approach to surveillance for peritoneal metastasis. *World Journal of Surgical Oncology*. 2016;14(1):243. DOI: 10.1186/s12957-016-0996-0

© 2017 Janež and Mihelčič; This is an Open Access article distributed under the terms of the Creative Commons Attribution License (<http://creativecommons.org/licenses/by/4.0>), which permits unrestricted use, distribution, and reproduction in any medium, provided the original work is properly cited.

Peer-review history:

The peer review history for this paper can be accessed here:
<http://sciencedomain.org/review-history/21337>