



Nasopharyngeal Carcinoma Mimicking Sinonasal Undifferentiated Carcinoma

Yuszaini A. B. ^{a*}, Zalilah Musa ^b and Nur Hidayah ^c

^a Department of Otorhinolaryngology, Sultan Ahmad Shah Medical Center @IIUM, Kuantan, Pahang, Malaysia.

^b Department of Otorhinolaryngology, Hospital Sultanah Nur Zahirah, Kuala Terengganu, Terengganu, Malaysia.

^c Department of Radiology, Hospital Kemaman, Kemaman, Terengganu, Malaysia.

Authors' contributions

This work was carried out in collaboration among all authors. All authors read and approved the final manuscript.

Article Information

DOI: 10.9734/JCTI/2023/v13i2233

Open Peer Review History:

This journal follows the Advanced Open Peer Review policy. Identity of the Reviewers, Editor(s) and additional Reviewers, peer review comments, different versions of the manuscript, comments of the editors, etc are available here: <https://www.sdiarticle5.com/review-history/105375>

Case Study

Received: 27/06/2023

Accepted: 30/08/2023

Published: 11/09/2023

ABSTRACT

Nasopharyngeal carcinoma (NPC) is a tumor arising from the epithelial cells that covers the surface and lining of the nasopharynx. It is divided into keratinizing squamous cell carcinoma, and non-keratinizing carcinoma, which can be further divided into differentiated and undifferentiated subtypes. Symptoms of NPC can be obscure due to its anatomic location. On the other hand, sinonasal undifferentiated carcinoma defined as a highly aggressive and clinicopathologically distinctive carcinoma of uncertain histogenesis that typically presents with locally extensive disease. The present report is a case of 66-year-old Malay woman with underlying hypertension, hyperlipidemia and ischemic heart disease presented with swelling over the left upper palate for 5 months associated with the nasal symptoms. Cranial nerves were intact. Nasal endoscopy of the left nose revealed a mass occupying the left nasal cavity with histopathology of sinonasal undifferentiated carcinoma. However, CT scan result showed huge left nasopharyngeal carcinoma with local invasion and intracranial extension.

*Corresponding author: Email: yuszainiazri@gmail.com, yuszaini.azri@gmail.com;

Keywords: Nasopharyngeal carcinoma; sinonasal carcinoma.

1. INTRODUCTION

“Nasopharyngeal carcinoma (NPC) is a tumor arising from the epithelial cells that cover the surface and line of the nasopharynx” [1]. “It is a distinct form of head and neck that differs from other malignancies of upper aerodigestive tract in terms of its etiology, epidemiology, pathology, clinical presentation, and response to treatment” [2]. “There is an annual incidence of 0.5-2.0 cases in 100,000 in the US and Europe, although numbers as high as 25 per 100,000 may be seen in endemic countries such as China” [3]. “In Malaysia, majority of the cases (75%) presented at stage III/IV, with neck mass being the most common presenting features (42%)” [4]. “World health Organization, divided NPC on a pathological basis into three histological subtypes i.e keratinizing squamous cell carcinoma, non-keratinizing carcinoma, which can be further divided into differentiated and undifferentiated subtypes” [5]. “Symptomatically NPC most often presents with nasal and ear complaints from sinus congestion and epistaxis, to otalgia and tinnitus. Physical exam classically reveals a neck mass or masses, and cranial nerve involvement is not common” [6]. “Treatment of early and locally advanced disease is typically nonsurgical because of the proximity of nearby vital structures. Thus, there is a strong role for non-invasive therapy in the form of radiation ± chemotherapy, which is considered standard of care for this disease” [3].

“Sinonasal undifferentiated carcinoma (SNUC) is a poorly differentiated carcinoma that arises from Schneiderian mucosa which lines the nasal cavity and paranasal sinuses. It is very rare disease with unknown exact incidence rate. SNUC first described by Frierson and colleagues in 1986, is a high-grade, round cell neoplasm of the sinonasal tract” [7]. “WHO classified SNUC as a highly aggressive and clinicopathologically distinctive carcinoma of uncertain histogenesis that typically presents with locally extensive disease” [8]. “Usually patients present with symptoms such as nasal obstruction and epistaxis, and due to its invasive nature, it results in proptosis, cranial nerve palsies, visual disturbance, and pain” [9]. The ideal therapy for SNUC remains controversial, but multimodality therapy, including neoadjuvant chemotherapy followed by surgery in resectable cases, may result in improved prognosis.

2. CASE PRESENTATION

A 66-year-old Malay woman with underlying hypertension, hyperlipidemia and ischemic heart disease was referred by OMFS team for expert opinion on left maxillary sinus as noted haziness over left maxillary sinus in CBCT maxilla and mandible. Patient initially presented with painless swelling over the left upper palate for 5 months associated with left eye watery discharge for 3 months. Patient also complained of frequent rhinorrhea of the left nose associated with nasal blockage and epistaxis for 1 year. Otherwise, there was no smell disturbance. Furthermore, she also complained of bilateral hearing loss with tinnitus more over the left ear.

On examination, there was visible facial asymmetry over the left cheek due to swelling with intact facial nerve as shown in Fig. 1. Other cranial nerves were also intact. Intraorally noted swelling at the left upper palate extending until the soft palate as shown in Fig. 2. There were no palpable neck lymph nodes and systemic examination was normal. Nasal endoscopy revealed polypoidal nasal mucosa with mass occupying left nasal cavity as shown in Fig. 3. There was contact bleeding of the mass upon stimulation. Bleeding was secured with ribbon gauze soaked with cocaine. Right nasal cavity was congested with hypertrophied inferior and middle turbinate. Biopsy was planned after patient withheld his glyprin for 5 days. Pure tone audiometry showed mild to moderate hearing loss with notch at 4-8kHz over right ear with tympanometry type C and moderate mixed hearing loss over the left ear with tympanometry type B.

Biopsy of the left nasal cavity's mass was taken. After the biopsy, patient was admitted with nasal packing as noted oozing of blood over the biopsy site. Patient was able to be discharged on the next day. Histopathology (HPE) result came out as sinonasal undifferentiated carcinoma. Patient was scheduled for CT base of skull till abdomen. However, CT scan reported as highly suggestive of a huge left nasopharyngeal carcinoma with local invasion and intracranial extension. Case was discussed back with pathologist as HPE result was contradicting with radiological findings and was told to correlate with clinical and radiologically as it still can be NPC.

This patient was also seen by ophthalmology team and treated as left nasolacrimal duct

obstruction most probably secondary to compression of left nasal mass.

mass also erodes left wall of maxillary sinus with obliteration of lateral and medial pterygoid plate.

Patient was then referred to oncology team as nasopharyngeal carcinoma stage T4N2M0 for chemoradiotherapy.

3. DISCUSSION

“The nasal cavity and paranasal sinuses are referred to as the sinonasal tract, which is anatomically and embryologically different from the nasopharynx. They form a functional unit, which is lined by stratified squamous, respiratory-type pseudostratified columnar, and transitional (intermediate) epithelium” [10].

NPC presents most commonly as neck lump (60%), ear fullness (41%), hearing loss (37%), epistaxis (30%), nasal obstruction (29%), headache (16%), ear pain (14%), neck pain (13%), weight loss (10%), diplopia (8%). Sore throat and throat pain is rare presentation and its incidence is not documented [11].

“The most common initial symptoms of SNUC are epistaxis, facial pain, and nasal obstruction. More than one-half of all patient exhibit symptoms related to the eye, e.g., proptosis, cranial nerve palsies, diplopia, or decreased visual acuity. Because many of the early symptoms are similar to those of benign sinus disease, patients often delay seeking treatment and ultimately present with advance-stage disease” [12].

The present case revealed that, patient main complaint was swelling over the left palate which is quite unusual presentation for NPC. However, patient also had complained of left nasal blockage, epistaxis and left ear fullness and reduces hearing which can be both presentation of NPC and SNUC. Patient denied having any eye symptoms except for left eye discharge.

Diagnosis of NPC is made by the help of imaging studies and histopathology in addition to nasal endoscopy. Further in this case, nasal endoscopy had limitation in view the mass obstructing the view made difficulty in identifying the origin of the mass. The initial histopathological result from the mass reported as sinonasal undifferentiated carcinoma. The diagnosis of NPC was confirm after CT scan showed mass arising from left side of nasopharynx with involvement of parapharyngeal space and obliterating the left fossa of rosenmuller. The

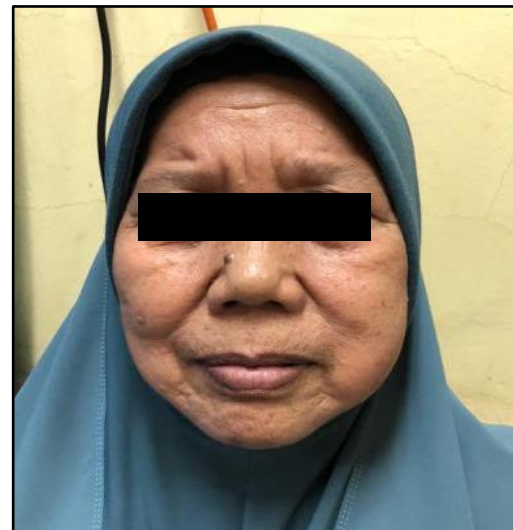

Fig. 1. Image showing swelling over left cheek

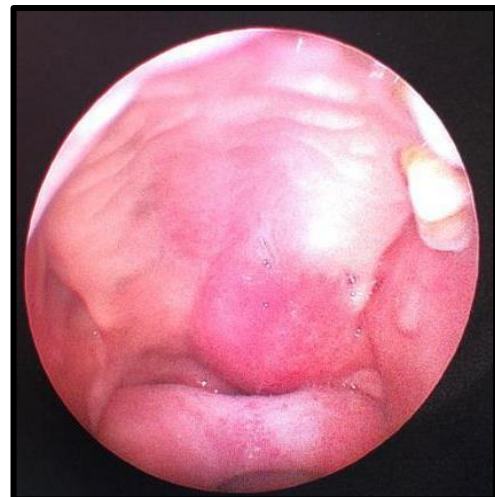

Fig. 2. Swelling over the left palate

“The most challenging differential diagnosis for SNUC include undifferentiated NPC. The cytologic features of undifferentiated NPC is similar to SNUC which are characterized by the presence of single cells, small loose clusters and occasional larger clusters, variably prominent nucleoli, and scant neoplasm. The clinical facts should aid in the differential diagnosis. The separation of these lesions is important because the mainstay of treatment for NPC is radiation therapy (often alone); the prognosis of NPC is much better than that of SNUC, 5-year-survivals around 60%” [7].

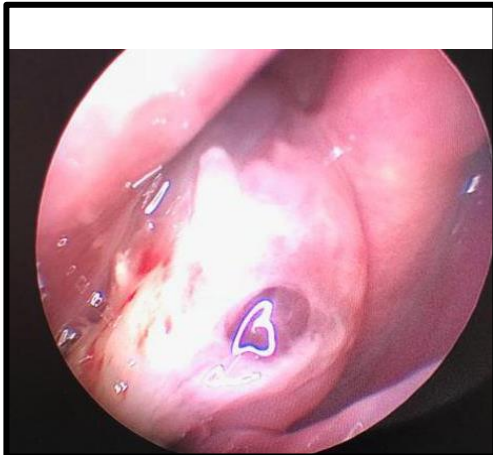


Fig. 3. Mass over left nasal cavity

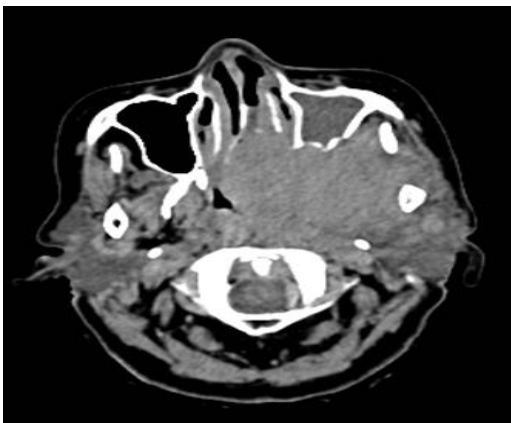

Fig. 4. CT scan revealed mass originate from left nasopharynx

4. CONCLUSION

To reach presumptive diagnosis, the presenting features and symptomatology and imaging studies with the help of histopathological examination is important to get a correct diagnosis and timely intervention. Correct diagnosis will direct the clinician towards proper management or proper outcome.

CONSENT

Informed consent was taken from the patient that involve in this study.

ETHICAL APPROVAL

As per international standard or university standard written ethical approval has been collected and preserved by the author(s).

ACKNOWLEDGEMENTS

The author would like to thank all staff and nurses of Hospital Kemaman for their kind assistance and providing facilities.

COMPETING INTERESTS

Authors have declared that no competing interests exist.

REFERENCES

1. Gupta R, Mohindroo NK, Azad R. Nasopharyngeal Carcinoma with uncommon Presentation. *Int J Head Neck Surg.* 2017;8(1):34-36
2. Keiji Tabuchi, Masahiro Nakayama, Bungo Nishimura, et al. Early Detection of Nasopharyngeal Carcinoma. *International Journal of Otolaryngology.* 2011; Article ID 638058, 6.
3. Courtney Pollard III, Shane M. Mesko, Lawrence E. Ginsberg, et al. Nasopharyngeal carcinoma with intranasal spread. *Clinical Case Reports.* 2017;5(10): 1682-1688
4. Mohamad I, Kosha MY. Submandibular mass a rare presentation of advanced nasopharyngeal carcinoma. *Malays Fam Physician.* 2013;8(3):40-2
5. Sandhu KS, et al. *Int J Otorhinolaryngol Head Neck Surg.* 2017;3(4):1117-1119.
6. Baba M, Dominguez LW, Patel A. A typical presentation of nasopharyngeal carcinoma. *Hematol Transfus Int J.* 2016; 2(4):00041
7. Andrew M, Bellizzi MD T. David Bourne. et al. The cytology features of Sinonasal undifferentiated Carcinoma and Olfactory Neuroblastoma. *Am J Clin Pathol.* 2008; 129:367-376
8. Bruce M. Wenig, MD. Undifferentiated Malignant Neoplasms of the Sinonasal Tract. *Arch Pathol Lab Med.* 2009;133.
9. Pradeep N, Ghorpade R. Sinonasal undifferentiated carcinoma with intracranial extension: Case report. *J Sci Soc.* 2016; 43:41-3
10. Bhattacharya J, Goswami BK. et al. Clinicopathological study, mass, sinonasal tract, nasopharynx. *The Egyptian Journal of Otolaryngology.* 2015; 31:98-104
11. *Indian J. Otolaryngol. Head Neck Surgery.* 2018;60 (January-March):82-83.

12. Judith Gorelick, Donald Ross, et al. Case series and Review of the literature.
Sinonasal Undifferentiated Carcinoma: Neurosurgery. 2000;47:3.

© 2023 Yuszaini et al.; This is an Open Access article distributed under the terms of the Creative Commons Attribution License (<http://creativecommons.org/licenses/by/4.0>), which permits unrestricted use, distribution, and reproduction in any medium, provided the original work is properly cited.

Peer-review history:

The peer review history for this paper can be accessed here:

<https://www.sdiarticle5.com/review-history/105375>