



CASE REPORT

A Rare Case of Enhancing Anterior Interhemispheric Racemose Neurocysticercosis with Foci of Calcification and Direct Parenchymal Extension

Anupama Chandrappa¹, Rajesh Raman^{1*}, Suchetha Satish¹

¹ JSS Medical College Hospital, JSS University, Mysore, India

* **Corresponding author.** Current address: Department of Radiology, JSS Medical College Hospital, JSS University, Mysore; Email: rajeshiyer81@gmail.com

OPEN ACCESS

© 2018 Chandrappa, Raman and Satish. This open access article is distributed under a Creative Commons Attribution 4.0 License (<https://creativecommons.org/licenses/by/4.0/>)

DOI: 10.7191/jgr.2018.1040

Published: 2/27/2018

Citation: Chandrappa A, Raman R, Satish S. A rare case of enhancing anterior interhemispheric racemose neurocysticercosis with foci of calcification and direct parenchymal extension. *J Glob Radiol.* 2018;4(1):Article 1.

Keywords: Neurocysticercosis, racemose, anterior interhemispheric fissure

Word count: 2,255

Abstract

Neurocysticercosis (NCC) refers to the central nervous system (CNS) infestation of the larvae of pork tapeworm *Taenia solium*. It is endemic in Central and South America, Asia and Africa. It most commonly presents as intraparenchymal subcentimetric ring enhancing lesions of variable ages (or size and duration) with surrounding vasogenic edema. The lesions calcify with time. Rarely, NCC can occur in extraparenchymal locations, within the subarachnoid space and ventricles. At these locations it is usually seen as a proliferative lobulated cystic mass without a scolex which is termed racemose neurocysticercosis. Racemose cysticerci do not show calcification, scolex, or enhancement.

We report a case of a 23-year-old man with a two-year history of headache. CT and MRI showed multilocular bubbly cystic mass with epicenter in the anterior interhemispheric fissure showing intraparenchymal extension into adjacent bilateral parasagittal frontal lobes. There was a central nodular calcification and mild peri-lesional vasogenic edema. Rim enhancement was observed in the cysts on post contrast study. The diagnosis of racemose cysticercosis was made on biopsy. Despite being racemose, our case showed coarse central calcification and rim enhancement of the cystic portions, which are rare entities and hence reported here. Direct intraparenchymal extension of racemose form of NCC has not been reported in the literature to date, and our case is the first of this kind to be reported.

Introduction

NCC is the most common parasitic infestation of the CNS and the most common cause of late-onset epilepsy in endemic areas (1-3). Cysticercosis has a predilection for the eyes, CNS and striated muscles due to high glycogen and glucose content within these cells. In the brain, it can affect the meninges, parenchyma, ventricles and subarachnoid space. Clinical presentation depends on the number, type, location and developmental stage of the cysticerci as well as the host immune response to the parasite (4,5). Diagnosis is suspected by computerized tomography (CT), magnetic resonance (MR) imaging and confirmed by immunological laboratory

tests and biopsy (1,4). Del Bruto et al. have proposed absolute, major, minor and epidemiological criteria for probable and definitive diagnosis of NCC (6).

Racemose neurocysticercosis refers to a rare form of NCC, with the cysts localized mainly in the subarachnoid space, cisterns or within the ventricles. Normally, the scolex is absent or degenerated and multiple complex small cysts resembling clusters of grapes may form, filling the cisterns or sulcal spaces (1,7).

Case report

A 23 year-old man presented with the complaint of an episode of generalized

tonic-clonic seizures two days prior. He reported having a dull headache for the past three years. There was no history of vomiting or visual complaints. He followed a vegetarian diet. General physical examination and fundus examination were normal. The hemogram and biochemical parameters were within normal limits. Plain CT scan images of the brain performed elsewhere two years ago were reviewed. It showed a 3.2 cm x 3.1 cm x 2.8 cm multilocular extra axial cystic mass in the anterior interhemispheric fissure, extending into adjacent bilateral parasagittal frontal lobes. The mass had a calcified focus in the center. The possibility of cystic glioma and extra-ventricular central neurocytoma was considered at this time.

Contrast-enhanced MRI of the brain was performed at JSS Medical College Hospital in Mysore, India. It showed a 3.1 cm x 3.2 cm x 3.3 cm multilocular bubbly mass in the anterior interhemispheric fissure extending into adjacent bilateral parasagittal frontal lobes and genu of the corpus callosum. The mass showed hyperintense signal on T2, hypointense signal on T1 and complete inversion on FLAIR sequences, following the CSF signal (Figure 1). Splaying of A2 segment of the right ACA was seen and the mass was closely abutting M1 segment of the right MCA. A central coarse focus of susceptibility artifact corresponding to calcification on CT was seen. Mild peri-lesional vasogenic edema was seen in the frontal lobe white matter. There was rim enhancement of the cystic portions on post contrast study (Figure 1). There was no

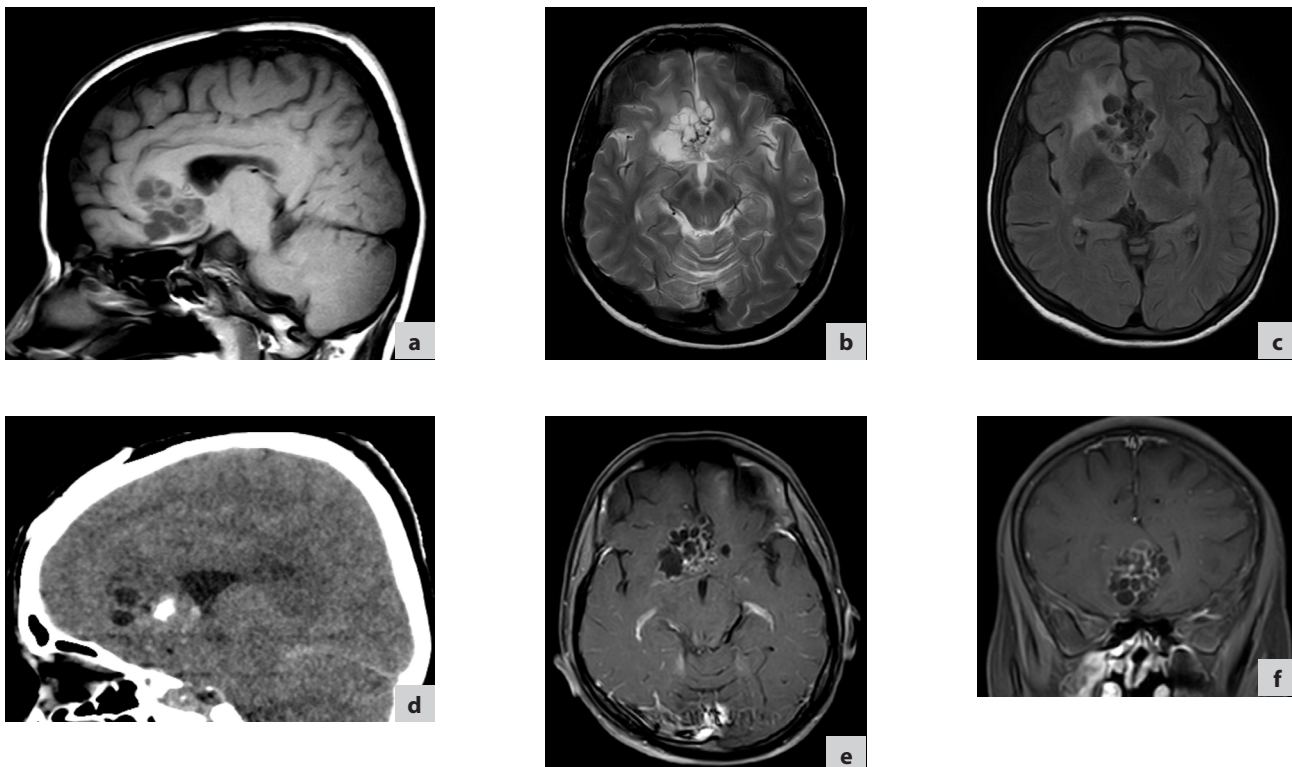
restricted diffusion. MR spectroscopy was performed to rule out neoplasm. It showed presence of lipid-lactate peak (Figure 2). There was no significant reduction in the N-acetylaspartate (NAA) peak and no significant increase in the choline peak, suggesting non-neoplastic aetiology. The rest of the cerebral parenchyma, cerebellum, ventricles, cisterns and extra-axial spaces were normal.

As there was no significant interval change in the size or appearance of the mass, and considering its close proximity to the septum pellucidum and the presence of mild perilesional edema, the differential diagnoses of low-grade cystic glioma versus extra-ventricular central neurocytoma were entertained. The possibility of cystic cranipharyngioma was not considered, as the sella, suprasellar regions and hypothalamus were normal. The patient underwent right frontal craniotomy and excision biopsy. The intra-operative appearances correlated well with MRI findings.

Pathological findings

Gross specimen showed multiple greyish white membranous tissue bits with a few fluid-filled vesicular structures. Microscopic examination showed a small area of poorly preserved glial tissue and parasitic cyst. The cyst wall showed a cuticle layer and loose myxoid layer. However, scolex could not be appreciated. Aggregates of lymphocytes and areas of

Figure 1. a) Sagittal T1; b) Axial T2; c) Axial FLAIR; d) Sagittal CT; e) Post-contrast axial T1 fat sat; f) Post-contrast coronal T1 fat sat. Bubbly cystic anterior interhemispheric lesion similar to CSF signal intensity abutting the septum pellucidum noted. On CT (d) there is coarse central calcification. Enhancement of the walls noted in post-contrast images (e, f).



hemorrhage were seen. A diagnosis of racemose variant of neurocysticercosis was made on histology.

Discussion

Neurocysticercosis is endemic in most of the developing countries. It is transmitted through ingestion of water and food contaminated by larval forms of *Taenia solium* (8-10). It is classified as cisternal-subarachnoid, parenchymal, intraventricular or mixed type, depending on the location (11). The parenchyma is the commonest location, followed by the subarachnoid space and ventricles (12). Rare cases of spinal NCC are also reported.

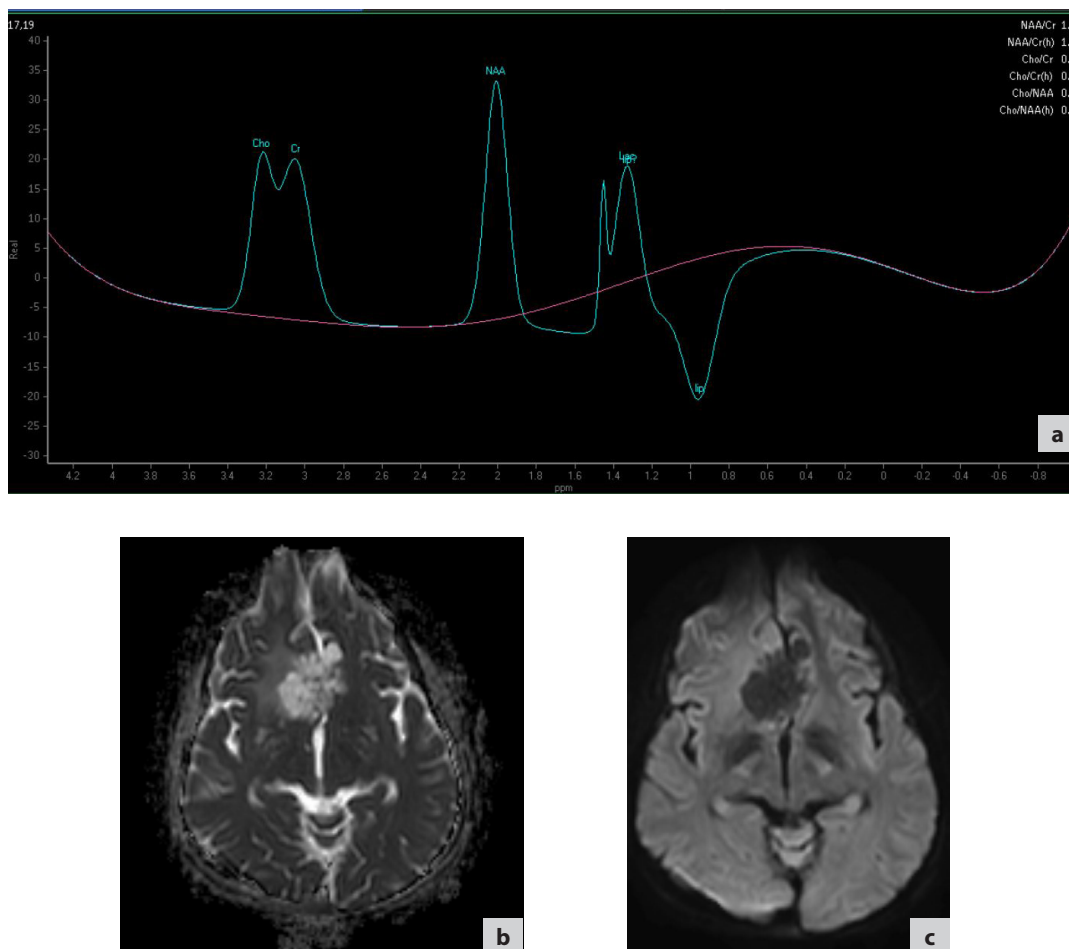
NCC can manifest as cellulosaes or racemose forms. The cellulosaes form is the most common and can be either intraparenchymal or intraventricular in location. It is characterized by subcentimetric cysts with a scolex. It undergoes developmental changes as vesicular, colloidal vesicular, granular nodular and calcified nodular stages according to which the imaging features change (11,13). The colloidal vesicular form elicits extensive peri-lesional inflammatory changes. However, such changes in the morphology of cysts are not seen in racemose NCC (14).

The racemose form of NCC is rare and has been found in 3.5% of neurocysticercosis patients. It commonly involves basal cisterns and sylvian fissures (12). It appears as an agglomerate of multiple, translucent thin-walled vesicles in the subarachnoid space, usually without a scolex (1,7,15). They arise from segmentation of cysticercosis cellulosaes with sprouting of new cysts and degeneration of the scolex, and are nonviable, degenerated interconnected bladders of various sizes (12). Some authors consider it an infestation caused by a different variety of cestode, namely *Taenia multiceps* or *Taenia cerealis* (16). According to Sharma et al., the racemose variety is very rare in India (14). Direct intraparenchymal extension of racemose form of NCC has not been reported in the literature to date, and ours is the first reported case of this kind.

Epilepsy and headache are the most common manifestations of NCC. Other clinical features include paraparesis, psychiatric symptoms, stroke and dementia (4,8). Rare clinical manifestations are the symptoms of meningitis: ependymitis and ventriculitis. Our patient presented with headache and epilepsy.

Litt et al. have found that the degenerated scolex could be present in racemose form of gross specimens (4). On MRI,

Figure 2. a) MRS showing an elevated lipid-lactate peak; b) Lesion showing hyperintense signal on ADC; c) Lesion showing hypointense signal on DWI, suggesting absence of diffusion restriction.



the cysts follow CSF signal intensity and scolex is generally not seen. In our case also, all the cysts followed CSF signal intensity and no scolex was identified in any of them. Conglomeration of the cysts resemble a bunch of grapes (13). Such a resemblance was observed in our case.

The racemose cysts do not show wall enhancement after intravenous contrast injection. However, there was enhancement of the walls in our case. Larger cysts may result in mass effect, leading to widening of the adjacent subarachnoid space (13). A degenerating cyst may elicit inflammatory reaction, cause arachnoiditis, hydrocephalus and surrounding leptomeningeal enhancement. These complications were not seen in our case.

The inflammatory process may involve corresponding arteries, cause vasculitis and even result in infarction (13). The causes of infarction in cysticercosis are cysticercus-induced vasculitis, thrombosis of cortical arteries/small perforators and weakening of the vessel wall by mycotic aneurysms (17). Infectious (mycotic) aneurysms are commonly associated with subarachnoid NCC (17). However, our case did not show these features.

The imaging differential diagnoses for racemose NCC are neuroglial cysts, arachnoid cyst, porencephaly and echinococcal cysts. Lack of edema around the cystic lesion differentiates arachnoid cyst and echinococcal cyst from NCC. The echinococcal cysts are usually larger than NCC and show pyruvate peak on MRS. No pyruvate peak was observed in our study. The differential diagnoses for cystic masses with calcification, perilesional edema and without restricted diffusion in the anterior interhemispheric fissure and frontal lobe region include oligodendrogliomas, central neurocytomas with extra ventricular extension, ganglioneurocytoma, pleomorphic xanthoastrocytoma and pilocytic astrocytoma. In all these neoplasms, MRS shows elevated choline peak with variable reduction in NAA peak, depending on the grade of the tumor. However, our case showed no significant reduction in NAA peak and no significant increase in choline peak, consistent with non-neoplastic etiology.

Serological tests may also be used for the diagnosis of NCC. The most reliable serological test is electroimmunotransfer blott (EITB) using purified antigenic extracts. EITB detects antibodies for *T. solium* antigens in serum with a sensitivity and specificity of nearly 100% for DJ unbound fraction of the *T. solium* antigen (18). The detection of anticysticercal antibodies on CSF enzyme-linked immunosorbent assay (ELISA) is 87% sensitive and 95% specific for the diagnosis of NCC. It is a useful diagnostic test in areas with limited access to the EITB assay (19). The sensitivity of antigen detection tests is generally better if performed on CSF than on serum (20). However, serology was not performed in our case.

NCC is treated by antiedema measures, oral steroids and cysticidal drugs like praziquantel and albendazole. Extra-parenchymal cysticercosis is associated with poor response to oral therapy and requires surgery (13).

Conclusion

Racemose NCC presents as conglomeration of cysts in the subarachnoid space with the appearance of a bunch of grapes. Usually, scolex, wall enhancement, calcification and intraparenchymal extension are not seen in racemose NCC. Our case showed significant wall enhancement, central coarse calcification and direct intraparenchymal extension, mimicking the imaging pattern of central neurocytoma except for extra ventricular location. The possibility of racemose NCC should be considered in cystic lesions of the brain.

Conflict of interest

The authors report no conflict of interest.

Acknowledgments

The authors are grateful to Dr. Jayashree, Professor & Head, Department of Pathology and Dr. Kamal Kumar Sen, Professor & Head, Radiology for their support.

References

1. Lerner A, Shiroishi M, Zee C, et al. Imaging of neurocysticercosis. *Neuroimag Clin N Am*. 2012; 22: 659–676.
2. Kimura-Hayama E and Criales J. Neurocysticercosis: Radiologic-pathologic correlation. *Radiographics*. 2010; 30: 1705–1719.
3. Carpio A, Escobar A and Hauser WA. Cysticercosis and epilepsy: A critical review. *Epilepsia*. 1998; 39: 1025–1040.
4. Litt AW, Mohuchy T. Case 10: neurocysticercosis. *Radiology*. 1999; 211: 472–476.
5. Lucato LT, Guedes MS, Sato JR, Bacheschi LA, Machado LR, et al. The role of conventional MR imaging sequences in the evaluation of neurocysticercosis: impact on characterization of the scolex and lesion burden. *AJNR Am J Neuroradiol*. 2007;28: 1501–1504.
6. Del Brutto OH, Wadia NH, Dumas M, Cruz M, Tsang VC, et al. Proposal of diagnostic criteria for human cysticercosis and neurocysticercosis. *J NeuroSci*. 1996;142: 1–6.
7. Castillo M. Imaging of neurocysticercosis. *Semin Roentgenol*. 2004; 39: 465–473.
8. Del Brutto OH. Neurocysticercosis: A Review. *Sci World J*. 2012: 1–8.
9. Sotelo J, Del Brutto OH. Brain cysticercosis. *Arch Med Res*. 2000; 31: 3–14.
10. Takayanagui OM. Neurocysticercosis. *Arq Neuropsiquiatr*. 2013;71: 710–713.
11. Noujaim SE, Rossi MD, Rao SK, Cacciarelli AA, Mendonca

- RA, et al. CT and MR imaging of neurocysticercosis. *AJR Am J Roentgenol.* 1999;173: 1485-1490.
12. Mahale RR, Mehta A, Rangasetty S. Extraparenchymal (Racemose) neurocysticercosis and its multitude manifestations: A comprehensive review. *J Clin Neurol.* 2015 Jul;11(3):203-211.
 13. García HH, Del Brutto OH. Imaging findings in neurocysticercosis. *Acta Trop.* 2003;87: 71-78.
 14. Sharma S, Modi M, Lal V, Prabhakar S, Bhardwaj A, Sehgal R. Reversible dementia as a presenting manifestation of racemose neurocysticercosis. *Ann Indian Acad Neurol.* 2013;16:88-90.
 15. Singh S, Gibikote SV, Shyamkumar NK. Isolated fourth ventricular cysticercus cyst: MR imaging in 4 cases with short literature review. *Neurol India.* 2003;51: 394-396.
 16. Ghosh D, Dubey TN, Prabhakar S. Brain parenchymal, subarachnoid racemose, and intraventricular cysticercosis in an Indian man. *Postgrad Med. J.* 1999; 75:164-167.
 17. Garcia HH, Del Brutto OH, Nash TE, White AC, Tsang VC, Gilman RH. New concepts in the diagnosis and management of neurocysticercosis (*Taenia solium*). *Am J Trop Med Hyg.* 2005; 72: 3–9.
 18. Deckers N, Dorny P. Immunodiagnosis of *Taenia solium* taeniosis/cysticercosis. *Trends Parasitol.* 2010;26:137–44.
 19. Machado GA, de Oliveira HB, Gennari-Cardoso ML, Mineo JR, Costa-Cruz JM. Serodiagnosis of human neurocysticercosis using antigenic components of *Taenia solium* metacestodes derived from the unbound fraction from jacalin affinity chromatography. *Memórias do Instituto Oswaldo Cruz.* 2013;108(3):368-375.
 20. Michelet L, Fleury A, Sciutto E, Kendjo E, Fragoso G, Paris L, et al. Human neurocysticercosis: comparison of different diagnostic tests using cerebrospinal fluid. *J Clin Microbiol.* 2011;49:195–200.